

Localized Intra-Abdominal Kikuchi-Fujimoto Disease: a Case Report and Review of the Literature

Hideto TERANISHI, Kozo KAWASAKI, Atsuko SASAKI*, Hiroki FUJIMOTO, Mika INOUE, Ayaka MONJU, Tokio WAKABAYASHI, Hiroto AKAIKE, Tetsuya YAMAGUCHI, Satoko OGITA, Keiko ODA, Kihei TERADA and Kazunobu OUCHI

*Department of Pediatrics, Kawasaki Medical School
577 Matsushima, Kurashiki city, Okayama 701-0192, Japan*

**Fukuoka Children's Hospital and Medical Center for infections disease*

Accepted for publication on September 29, 2008

ABSTRACT

We described a nine-year-old boy with Kikuchi-Fujimoto disease involving localized the intra-abdominal lymph nodes who suffered from persistent fever.

Elevated serum soluble IL2 receptor and urine β 2-microglobulin levels in this patient indicated that the clinical findings were due to hypercytokinemia. Abdominal magnetic resonance imaging with gadolinium enhancement revealed multiple enlarged lymph nodes in the periaortic and supramesentric artery regions, which had low signal intensity on short inversion time inversion-recovery imaging. Since it could not be determined if a malignant lymphoma was present from laboratory and imaging studies, we recommended resection of the involved lymph nodes to make a definitive diagnosis and decide whether or not to administer steroids.

Key words ① Kikuchi-Fujimoto disease ② subacute necrotizing lymphadenitis
③ soluble IL2 receptor

Kikuchi-Fujimoto disease (KFD), also known as subacute necrotizing lymphadenitis, is a benign and self-limiting disease with symptoms and signs of fever, eruption, and lymphadenopathy^{1,2}. Although KFD was first reported in Japan, it has recently been reported in countries other than ones in East Asia³. The cervical lymph nodes are mainly involved in KFD, and the diagnosis is made from pathological findings of the resected nodes.

Only two cases of children with intra-abdominal lymph nodes involvement have been reported: a 14-year-old girl and a 15-year-old girl^{4,5}. However, when making a differential diagnosis in patients with fever of unknown origin, KFD should be considered even if the surface lymph nodes are not palpable. We present here a case of KFD involving localized intra-abdominal lymph nodes because the diagnosis was difficult without a biopsy despite close evaluations aimed at identifying malignant lymphoma.

His white blood cell count was 3,500 / μ l, with 49% neutrophils, 1% eosinophils, 36% lymphocytes, and 13% monocytes. His hemoglobin level was 12.1 g/dl, and his platelet count was 235,000 cells/ μ l. The serum levels of aspartate aminotransferase, alanine aminotransferase, alkaline phosphatase, lactic dehydrogenase, and C-reactive protein were 394 IU/L, 759 IU/L, 545 IU/L, 663 IU/L, and 0.39 mg/dL, respectively. His glucose, bilirubin, total protein, albumin, globulin, total cholesterol, blood urea nitrogen, creatinine, uric acid sodium, potassium, and chloride levels were normal. His ferritin and soluble IL-2 receptor were 380ng/ml and 875 U/ml. Natural killer cell activity was 15%. And β 2 microglobulin in urine was 1648 μ g/L. Bone marrow aspiration revealed normal findings except for some hemophagocytosis.

A CT scan of the abdomen disclosed enlarged mesenteric lymph nodes (Fig.1A). No organomegaly or ascites was seen. A chest CT scan was normal. Ga nuclear scanning revealed mild uptake in the midline region. Abdominal magnetic resonance imaging with gadolinium enhancement revealed multiple enlarged lymph nodes in the periaortic and supramesenteric artery regions (Fig.1B). The regions revealed low signal intensity on short inversion time inversion-recovery imaging (Fig.1C). Although acetoaminophen was given, the patient remained febrile. The mesenteric lymph nodes were biopsied by laparoscopy on seventh hospital day. Administration of diclofenac sodium, which was administered as an analgesic, relieved his fever and abdominal pain. However, when it was withdrawn on his 14th hospital day, his body temperature went up to 39°C, an eruption devel-

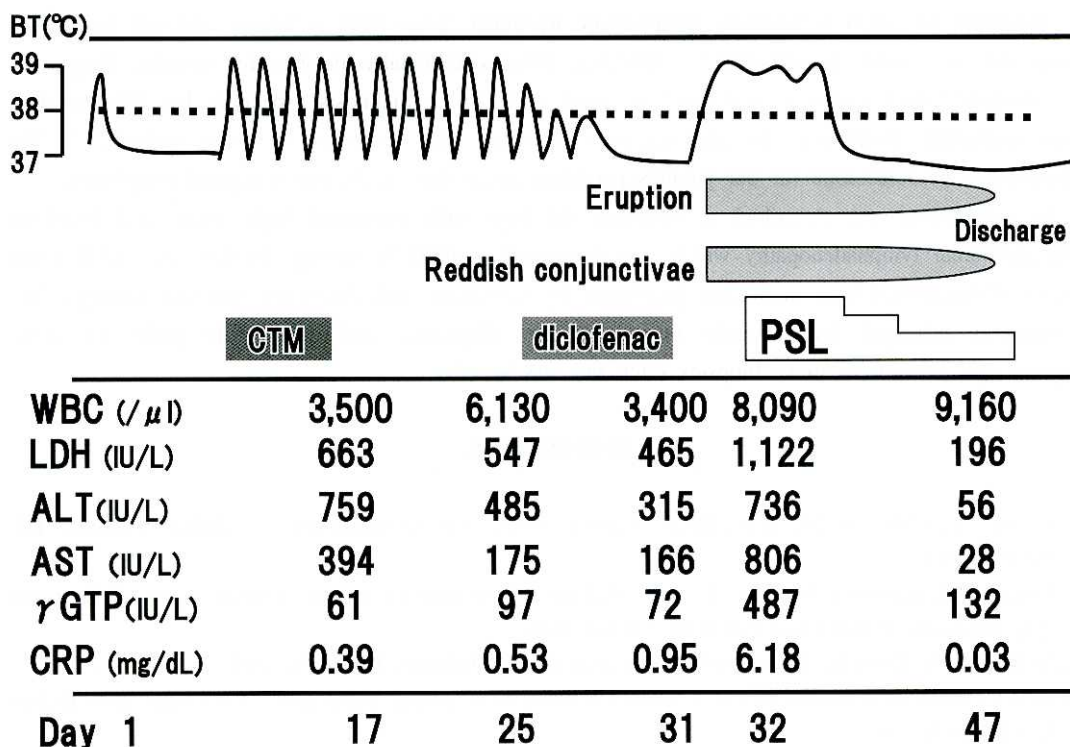


Fig. 2 Clinical course

CTM: cefotiam PSL: prednisolone

oped on his trunk and the bilateral conjunctivae became reddish. A histopathological examination of resected lymph nodes revealed abundant karyorrhectic debris and reactive histiocytes, and a diagnosis of KFD was made (Fig.1D). Prednisolone was administered orally on the following day and his fever fell and the rash disappeared. He was discharged on his 29th hospital day. Thereafter prednisolone was tapered off. No symptoms and signs have recurred for a year (Fig.2).

DISCUSSION

The cause of KFD remains poorly understood. We found a moderate increase in serum soluble IL2 receptor (sIL2R). Since elevated levels of sIL2R have been reported in hematologic malignancies that express CD25 as well as in inflammatory diseases, especially in the active phase, measurement of sIL2R could not differentiate KFD from malignant lymphoma⁶. The elevation of the sIL2R value could reflect activated T-cell responses, and moderate increases in ferritin and $\beta 2$ microglobulin in urine might reflect hypercytokinemia, which causes leukocytopenia and hypertransaminasemia.

We attempted to diagnose the patient's condition from imaging studies, but KFD has no specific radiological features. Kwon *et al* observed lymph nodes with no specific signal intensity being usually affected, in their CT findings⁷. In the magnetic resonance findings of our case, although the area of necrosis had a lower signal than non-necrotic areas on T2-weighted images, the intensity was homogeneous. Gallium-67 scintigraphy of the involved lymph nodes in this case showed uptake, as in the KFD patients described by Elshatife *et al*⁸.

Treatment for KFD is basically symptomatic treatment. Since KFD is benign and self limiting, a "wait and see" policy is adequate^{1,2}. However, fever occasionally persists for months. Biopsy of the involved lymph nodes is warranted to make a definitive diagnosis, especially for differentiation from malignant lymphoma. In addition, fever subsides after excision in some patients¹⁻³. We administered prednisolone for our patients persistent fever after excluding malignant lymphoma.

In conclusion, we described a nine-year-old boy with persistent high fever and localized intra-abdominal lymphadenopathy which was diagnosed as KFD by biopsy. In this case, KFD could not be distinguished from malignant lymphoma by laboratory and diagnostic imaging findings. We recommend principal lymph node resection from diagnostic and therapeutic point of view. Laparoscopic procedures make biopsies safer and less invasive.

REFERENCES

- 1) Lee KY, Yeon YH, Lee BC, *et al.*: Kikuchi-Fujimoto disease with prolonged fever in children. *Pediatrics* **114**: 752-756, 2004
- 2) Lazzareschi I, Barone G, Ruggiero A, *et al.*: Pediatric Kikuchi-Fujimoto disease: a benign cause of fever and lymphadenopathy. *Pediatr Blood Cancer* **10**: 119-123, 2006
- 3) Lin HC, Su CY, Huang SC: Kikuchi's disease in asian children. *Pediatrics* **115**: 92-96, 2005
- 4) Rudin C, Wernli R, Rutishauser M, *et al.*: Mesenterial histiocytic necrotizing lymphadenitis. Case report. *Helv Paediatr Acta* **42**: 35-40, 1987
- 5) Yabe H, Sinzato I, Hashimoto K: Necrotizing lymphadenitis presenting as mesenteric lymphadenopathy. *Rinsho*

Ketsueki **40**: 658-662, 1999

- 6) Kuuliala A, Soderlin M, Kautiainen H, *et al.*: Circulating soluble interleukin-2 receptor level predicts remission in very early reactive arthritis. *Scand J Rheumatol* **34**: 372-375, 2005
- 7) Kwon SY, Kim TK, Kim YS, *et al.*: CT Findings in Kikuchi disease: analysis of 96 cases. *AJNR Am J Neuroradiol* **25**: 1099-1102, 2004
- 8) Elshafie OT, Woodhouse NJ, Hussein SS, *et al.*: Gallium-67 lymph node localization in toxic Kikuchi-Fujimoto's disease. *Saudi Med J* **24**: 417-418, 2003