

An ileal perforation after infliximab treatment for crohn's disease in a heart transplant patient : A case report

Kazuki YAMASHITA ¹⁾, Yasuo OKA ¹⁾, Hideo OKUMURA ¹⁾, Hideo MATSUMOTO ¹⁾
Atsushi URAKAMI ¹⁾, Toshihiro HIRAI ¹⁾, Tsukasa TSUNODA ¹⁾, Kenichi TARUMI ²⁾
Ken HARUMA ²⁾

*1) Division of Gastroenterology, Department of Surgery, 2) Division of Gastroenterology, Department of Medicine,
Kawasaki Medical School, 577 Matsushima, Kurashiki, 701-0192, Japan*

ABSTRACT There is controversy over the degree of inflammatory bowel disease activity after transplant. We herein report the case of a patient who presented with an ileal perforation after infliximab treatment for Crohn's disease in a heart transplant patient under immunosuppressive therapy. A 30-year-old male with an 11-year history of Crohn's disease underwent a heart transplant. Five years after the transplant, he presented symptoms consistent with intermittent small bowel obstruction related to Crohn's disease and received infliximab therapy. Three months after the induction of the therapy, he presented with sudden intense abdominal pain and an emergent laparotomy revealed fecal panperitonitis due to a perforation of the distal ileum. The long-term usage of immunosuppressive agents, especially steroids, before the induction of infliximab may have an unfavorable effect on Crohn's disease treatment.

(Accepted on October 29, 2007)

Key words : **Complication , Crohn's disease , Infliximab , Transplant**

INTRODUCTION

The safety and efficacy of infliximab, a chimeric monoclonal immunoglobulin antibody to tumor necrosis factor, has been established in a number of controlled trials for the treatment of moderate to severe active and fistulizing Crohn's disease (CD)^{1,2)}. However, CD is an idiopathic disorder which most likely has an autoimmune etiology³⁾. We herein report the case of a heart transplant patient under immunosuppressive therapy who presented with an ileal perforation after

infliximab treatment for CD.

CASE REPORT

A 30-year-old Japanese male with an 11-year history of CD underwent a heart transplant for dilated cardiomyopathy in the USA in 1997. After the transplant, initially he was maintained on an immunosuppressive regimen that included cyclosporine A (150-175 mg/day) and mycophenolate mofetil (1,500 mg/day). Two years later, prednisolone (2 mg/day) was added due to an allograft rejection.

Corresponding author
Kazuki Yamashita
Division of Gastroenterology, Department of Surgery,
Kawasaki Medical School, 577 Matsushima, Kurashiki,
701-0192, Japan

Phone : 81 86 462 1111
Fax : 81 86 462 1199
E-mail : kazuki@med.kawasaki-m.ac.jp

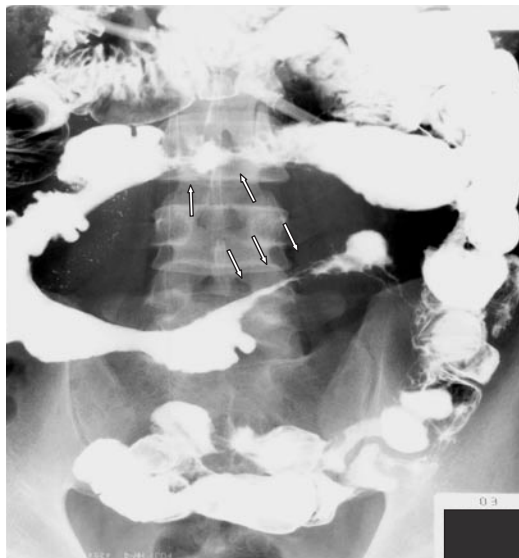

Fig. 1. A barium small bowel study before infliximab treatment demonstrates severe stenosis of the ileum (arrows).

The patient's post-transplant course was uneventful regarding his heart. Before the transplant and five years afterwards, he presented no symptoms related to CD and he had received no treatment for it. In 2002, he underwent an operation for an anal fistula and a peri-anal abscess as a result of CD. At that time, he presented with symptoms consistent with intermittent small bowel obstruction related to CD and he was therefore hospitalized to receive conservative therapy. In January 2003, a barium bowel series and enteroscopy demonstrated severe stenosis (Fig. 1), in addition to longitudinal deep ulcerations in the distal small intestine. Beginning in February 2003, he received infliximab (5 mg/kg of body weight) intravenously three times at weeks 0, 2, and 6 (Fig. 2). In the middle of March, his bowel symptoms had improved significantly and he could eat normally. A follow-up barium small bowel series and enteroscopy demonstrated an improvement in findings. The severe stenosis and longitudinal deep ulcerations had, respectively, become mild and superficial. During the infliximab treatment, he continued to receive the immunosuppressive regimen for the heart transplant. He was discharged

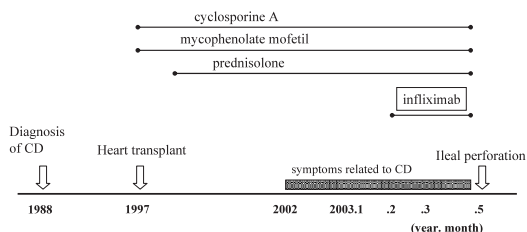


Fig. 2. The clinical course showed that there were no symptoms related to Crohn's disease for five years after the induction of immunosuppressive agents, and ileal perforation occurred three months after the start of infliximab therapy.

from the hospital on March 21. On May 7, he presented with sudden intense abdominal pain and was referred to our hospital (Fig. 3). An emergent laparotomy revealed fecal panperitonitis due to a perforation of the distal ileum. The inflammatory segment including the perforated segment of the ileum was removed and an ileal stoma was made. The specimen showed the perforation to be located at the bottom of a longitudinal ulceration (Fig. 4). The postoperative course was uneventful.

DISCUSSION

There are two contradictions in this case. Based on the theory that an inflammatory bowel disease (IBD) such as CD is an autoimmune disease, a flare-up of CD in a patient under immunosuppressive therapy is the first contradiction. There is controversy over

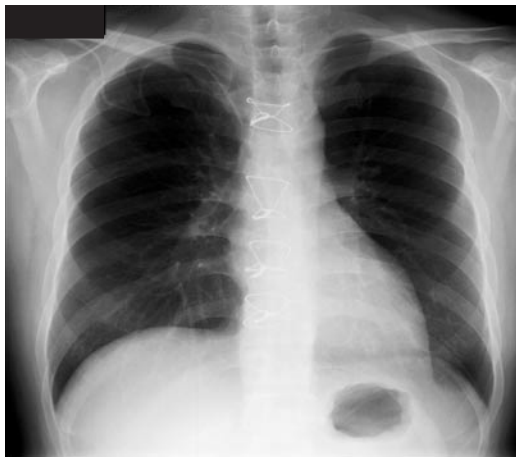

Fig. 3. Chest X-ray on emergent arrival is uneventful regarding his heart.

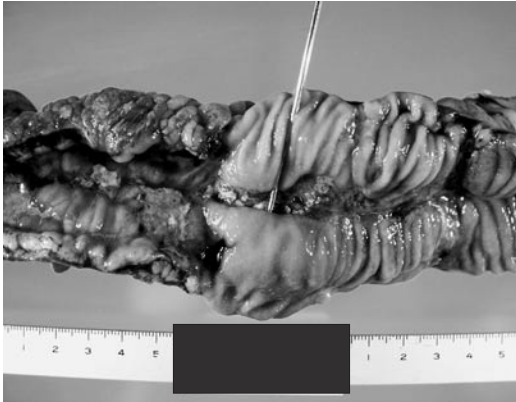

Fig. 4. The perforation is located at the bottom of the ulcer. The probe is inserted into the perforated part.

the degree of IBD activity after transplant. There have been reports of no difference in IBD activity and improvement in IBD symptoms^{4, 5)}. Riley *et al.*²⁾ reported 14 patients (0.2%) who developed IBD after a transplant despite immunosuppression, and the average time to IBD diagnosis was four years. In this case, a flare-up of CD occurred five years after the transplant. Cyclosporine, one of the immunosuppressive agents, might therefore not be an effective agent for remission in CD⁵⁾.

The subsequent intestinal perforation after the administration of infliximab, despite immunosuppression, is a second contradiction. Intestinal perforation is a very rare adverse event of infliximab¹⁾. The response to infliximab tends to improve when concomitant immunosuppressive therapy is given⁶⁾. Immunosuppressive agents should therefore be added to infliximab treatment to avoid an infusion reaction and/or the formation of antibodies to infliximab. Interestingly, the perforation developed after an improvement in his

condition following infliximab administration, and at first the infliximab seemed to be effective for this case. The specific issue in the present case is that the patient had been receiving long-term steroid therapy. The long-term usage of steroids might therefore suppress the inflammatory changes, such as thickness and fibrosis, in ulcers related to CD, thereby resulting in fragility of the inflammatory lesion. The long-term usage of immunosuppressive agents, especially steroids, before the induction of infliximab may therefore have an unfavorable effect on CD treatment.

REFERENCES

- 1) Hanauer SB, Feagan BG, Lichtenstein GR, *et al.* : Maintenance infliximab for Crohn's disease : the ACCENT I randomised trial. *Lancet* 359 : 1541-1549, 2002
- 2) Riley TR, Schoen RE, Lee RG, Rakala J : A case series of transplant recipients who despite immunosuppression developed inflammatory bowel disease. *Am J Gastroenterol* 92 : 279-282, 1997
- 3) Strober W, James SP: The immunologic basis of inflammatory bowel disease. *J Clin Immunol* 6 : 415-432, 1986
- 4) Shaked A, Colonna JO, Goldstein, Busuttil RW : The interrelation between sclerosing cholangitis and ulcerative colitis in patients undergoing liver transplantation. *Ann Surg* 215 : 598-603, 1992
- 5) McDonald JW, Feagan BG, Jewell D, Brynskov J, Stange EF, Macdonald JK : Cyclosporine for induction of remission in Crohn's disease. *Cochrane Database Syst Rev* 18 : CD000297, 2005
- 6) Rutgeerts P, Van Assche G, Vermeire S : Infliximab therapy for inflammatory bowel disease-seven years on. *Aliment Pharmacol Ther* 23: 451-463, 2006