

## An uncommon mechanism of airbag-related ocular injury

Shunji WAKAMIYA, Ichiro WATANABE, Junichi KIRYU

*Department of Ophthalmology, Kawasaki Medical School, 577 Matsushima, Kurashiki, 701-0192, Japan*

**ABSTRACT** There have been several reviews of airbag-related eye injuries. Regarding the action of airbags themselves, the mechanisms responsible for these injuries have been classified into three types: impact force on the eyes or objects between the occupant and the airbag, vented hot nitrogen gas, and surface abrasions. We report a patient who suffered severe corneal injury in a car crash while driving at low speed without wearing a seat belt. In this case, the action of the airbag was not among the well-known mechanisms. A 23-year-old man lost control of his automobile while accelerating from a stop signal, and crashed into a guardrail at approximately 30 km/h, while not wearing a seat belt. He was aware of his surroundings but, because he felt sleepy, he could not support his body in the driving position at the time of the sudden crash. His head moved along the surface of the airbag and his left eye impacted the end of the column shift lever. His half-rim eyeglasses were broken in the collision. A long, continuous oblique penetrating corneal injury, iris prolapse, and laceration of the upper and lower eyelids occurred. The corneal and skin lacerations were closed with sutures, and the iris prolapse was repaired. His final visual acuity was 20/20, although corneal opacity remained and the pupil was deformed slightly. With regard to the action of the airbag itself, the deployed airbag led to the subject's movement. This mechanism of injury has not been reported previously.

*(Accepted on March 25, 2009)*

**Key words :** Eye injury, Airbag inflation, Motor vehicle accident, Column shift lever, Seat belt

### INTRODUCTION

Many cases of ocular injuries associated with airbags have been reported, and there have been a number of reviews of the mechanisms responsible for these injuries. Stein *et al.*<sup>1)</sup>, Pearlman *et al.*<sup>2)</sup>, Ball and Bouchard<sup>3)</sup>, and Lee *et al.*<sup>4)</sup> reported blunt trauma by airbags, penetrating injuries by an eyeglass lens/frame breakage or a broken pipe stem, chemical burns due to vented hot nitrogen gas used

to inflate the airbag, and abrasion by the airbag fabric. Regarding the action of airbags themselves, these mechanisms are classified into three types: impact force on the eyes or objects between the occupant and the airbag, vented hot nitrogen gas, and surface abrasions.

Recently, we treated a patient with severe corneal injury received in an automobile accident. Although this case corresponds to a penetrating injury by

---

Corresponding author  
Shunji Wakamiya  
Department of Ophthalmology, Kawasaki Medical  
School, 577 Matsushima, Kurashiki, 701-0192, Japan

Phone : 81 86 462 1111  
Fax : 81 86 463 0923  
E-mail : oph@mtj.biglobe.ne.jp

an eyeglass lens or frame breakage, regarding the action of the airbag itself, the deployed airbag led to the subject's movement. This mechanism of injury has not been reported previously.

### CASE REPORT

A 23-year-old man lost control of his small Japanese small station wagon, the steering wheel of which was mounted on the right, while driving soon after stopping at a stop signal at around midnight. His vehicle crashed into a guardrail at a speed of approximately 30 km/h and had right front end damage and a tire blowout. As the driver-side airbag deployed upon impact and the occupant was not wearing a seat belt, his body was thrust forward and to the left. The patient reported that he was aware of his surroundings but because he felt sleepy he could not support his body in the driving position at the time of the sudden crash. As a result, his head touched the surface of the airbag, moved along it, and his left eye impacted the end of the column shift lever. His half-rim eyeglasses were broken in the collision.

Examination at the emergency department of our hospital revealed a long, continuous oblique penetrating corneal injury, iris prolapse, and laceration of the upper and lower eyelids. The corneal and skin lacerations were closed with

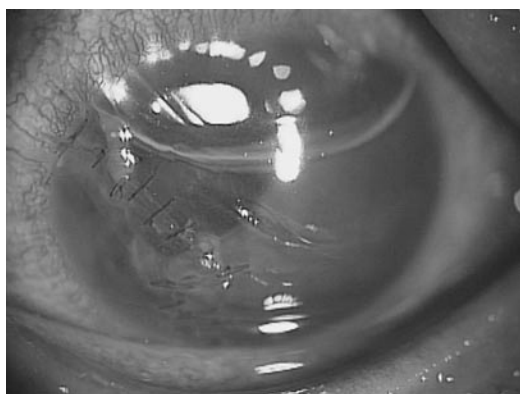


Fig. 1. Left eye the day after the injury  
The cornea was sutured and the iris was repaired. Long continuous oblique penetrating corneal injury was found.

sutures and the iris prolapse was repaired under general anesthesia (Fig. 1). There were no fragments of the broken lens on the surface or within the eye. Three months after the injury, the patient's visual acuity recovered up to 20/16. All of the corneal sutures were removed six months after the injury. The patient's final visual acuity was 20/20, although corneal opacity remained and the pupil was deformed slightly.

### DISCUSSION

In the case reported here, ocular injury occurred at the low speed of approximately 30 km/h. However, such injuries caused by airbag deployment do not always result in only minor damage despite occurring at low speed according to Stein *et al.*<sup>1)</sup>, Pearlman *et al.*<sup>2)</sup>, and Ball and Bouchard<sup>3)</sup>. Kim *et al.*<sup>5)</sup> reported a case of severe ocular injury, including periorbital fracture, hyphema, vitreous hemorrhage, and choroidal rupture of the macular area, associated with airbag deployment in a car crash at a speed of approximately 45 km/h. Six months after the injury, the patient's visual acuity recovered up to 20/20, although the injury in this case was thought to be severe. As the corneal penetrating injury reached the pupil area, this recovery may have been a coincidence.

In the present case, the airbag inflated due to a collision while the vehicle was moving forward and to the right. As the patient was not wearing a seat belt, he was thrust forward and to the left. As a result, his face slipped across the surface of the airbag and his left eye impacted the end of the column shift lever on the side of the steering wheel. In this case, the deployed airbag led to the subject's movement from the driving position to the impact with the column-shift lever. Stein *et al.*<sup>1)</sup> reported that an unbelted driver thrust forward and caught within the envelope of the deploying airbag would experience more impact from both forward thrust and the inflating airbag than a belted driver.

However, the airbag hardly transmitted its force to the eye in the present case. This raises the question of why this was the case. It was certain that the driver had not fallen asleep at the wheel prior to the crash because he reported that he had been aware of his surroundings and because his body should have received gravitation backwards during acceleration. There were no problems in the airbag system in this traffic accident. One possibility that, judging from the patient's report that his face touched the airbag and the fact that his eye did not receive direct force from the airbag, the airbag was likely to have finished the process of inflation when it came into contact with the driver's left eye. The other possibility is that, as his body was thrust forward and to the left, his face might have touched near the margin of the airbag during inflation. The inflating force of an airbag might have little effect on the eye near the margin of the airbag. But the truth is uncertain.

Regarding the action of the airbag itself, the deployed airbag led to the subject's movement from the driving position to the impact with the column-shift lever in this case. This mechanism is not among the well-known types: impact force on the eyes or objects between the occupant and the airbag, vented hot nitrogen gas, and surface abrasions. Airbags

have been shown to be effective in combination with the wearing a seat belt in collisions. If the driver had worn a seat belt or if the airbag had been a little larger, his eye would not have come into contact with the column-shift lever.

## CONCLUSION

Regarding the action of the airbag itself, the deployed airbag led to the subject's movement in this case. This mechanism has not been reported previously.

## REFERENCES

- 1) Stein JD, Jaeger EA, Jeffers JB: Air bags and ocular injuries. *Trans Am Ophthalmol Soc* 97: 59-82, 1999
- 2) Pearlman JA, Au Eong KG, Kuhn F, Pieramici DJ: Airbags and eye injuries: epidemiology, spectrum of injury, and analysis of risk factors. *Surv Ophthalmol* 46: 234-242, 2001
- 3) Ball DC, Bouchard CS: Ocular morbidity associated with airbag deployment: a report of seven cases and a review of the literature. *Cornea* 20: 159-163, 2001
- 4) Lee WB, O'Halloran HS, Pearson PA, Sen HA, Reddy SH: Airbags and bilateral eye injury: five case reports and a review of the literature. *J Emerg Med* 20: 129-134, 2001
- 5) Kim JM, Kim KO, Kim YD, Choi GJ: A case of air-bag associated severe ocular injury. *Korean J Ophthalmol* 18: 84-88, 2004