

High-salt and high-fat diets promote corpus atrophic gastritis in Mongolian gerbils

Keiko SHINOZAKI¹⁾, Tomoari KAMADA²⁾, Kuniaki SUGIU²⁾
Hiroaki KUSUNOKI³⁾, Noriaki MANABE³⁾, Akiko SHIOTANI²⁾
Jiro HATA³⁾, Fusako TERAMOTO¹⁾, Ken HARUMA²⁾

1) Faculty of Health Science and Technology, Department of Clinical Nutrition, Kawasaki University of Medical Welfare, 288 Matsushima, Kurashiki, 701-0193, Japan

2) Division of Gastroenterology, Department of Internal Medicine

3) Division of Endoscopy and Ultrasonography, Department of Clinical Pathology and Laboratory Medicine, Kawasaki Medical School, 577 Matsushima, Kurashiki, 701-0192, Japan

ABSTRACT *Helicobacter pylori* (*H. pylori*) infection and high dietary salt are known to be risk factors for gastric cancer. The purpose of this animal study was to determine whether excessive dietary salt and fat promote atrophic gastritis. Twenty-five 13-wk-old male Mongolian gerbils were used in this study. Fifteen animals received oral inoculation with *H. pylori* at 5 wks of age. All animals were fed a control diet (group C: 0.25% salt), a high-salt diet (group S: 10% salt), or a high-salt, high-fat diet (group SF: 10% salt, 40% fat) for 16 wks starting at the age of 14 wks. Among uninfected animals, the mucosal thickness of the corpus was significantly less in group S than in group C ($p < 0.01$), and the atrophy score was significantly higher in group S than in group C ($p < 0.05$). Among infected animals, the mucosal thickness of the corpus was the least in group SF. The inflammation score was significantly higher in groups S and SF than in group C (both $p < 0.05$). Excessive salt intake appears to promote atrophic gastritis in the corpus in Mongolian gerbils, and high fat intake may increase the effect of salt.

(Accepted on January 28, 2010)

Key words : *Helicobacter pylori*, Atrophic gastritis, Gerbil, High-salt high-fat diet

INTRODUCTION

Cancer of the stomach is amongst the most common malignancies worldwide, with some 870,000 new cases every year¹⁾. Areas with the highest incidence are in East Asia. In the United States and Europe, gastric cancer was once one of the most common cancers. However, mortality

rates have fallen dramatically over the last 50 years in all Western countries without any specific intervention, and gastric cancer is now rare²⁾. Differences in *Helicobacter pylori* species, racial genetics, and environmental factors are believed to be the main reasons for the differential incidence of gastric cancer in East Asia and Western countries.

Corresponding author

Ken Haruma

Division of Gastroenterology, Department of Internal Medicine, Kawasaki Medical School, 577 Matsushima, Kurashiki, 701-0192, Japan

Phone : 81 86 462 1111

Fax : 81 86 462 1199

E-mail : kharuma@med.kawasaki-m.ac.jp

Environmental factors, including dietary factors, particularly high dietary salt intake are known risk factors for gastric cancer³⁻⁶. A recent World Health Organization (WHO) /Food and Agriculture (FAO) report concluded that salt-preserved foods and salt intake probably increase the risk of stomach cancer⁷. Regarding the Japanese diet, salt intake has decreased somewhat; however, the average intake in men was 12.0 g/day in 2007⁸) and is still high compared to the North American intake of 7-8 g/day. The Japanese diet has also changed to reflect that of Western countries, with an increased intake of fat.

In 1996, Hirayama *et al.*⁹) reported the induction of gastric ulcer and intestinal metaplasia in Mongolian gerbils infected with *H. pylori*. Atrophy of the gastric membrane in Mongolian gerbils appears to be similar to *H. pylori*-induced lesions in humans. The purpose of this study was to determine whether excessive dietary salt and excessive fat intake promotes atrophic gastritis in Mongolian gerbils, with a focus on precarcinogenesis.

MATERIALS AND METHODS

Animals

Ten 13-week-old, specific pathogen-free male Mongolian gerbils (MGS/Sea; Kyudo Co., Ltd., Fukuoka, Japan) and 15 *H. pylori* (ATCC43504)-infected gerbils (MGS/Sea) were used in this study. Animals were orally inoculated at 5 wks of age. At 8 wks after inoculation, blood samples were obtained from the orbital plexus and anti-*H. pylori* antibodies were measured by enzyme-linked immunosorbent assay (ELISA) (Kyowa Medex Co., Ltd., Tokyo, Japan). Animals were assigned to one of five groups, two *H. pylori*-negative groups and three *H. pylori*-positive groups. Three or five animals were housed per plastic cage on paper chip bedding in an air-conditioned room with a 12-h light/dark cycle. The animal protocol for this experiment was approved by the Animal Care and Use Committee

of Kawasaki Medical School (No. 05-062).

Diet

Animals in the *H. pylori*-negative groups were fed a commercial diet containing 0.25% salt (group C: MF, 26.2% protein, 13.3% fat, 60.5% carbohydrate; Oriental Yeast Co., Ltd., Tokyo, Japan,) or 10% salt (group S: 10% salt MF; Oriental Yeast Co., Ltd.). *H. pylori*-infected animals were fed a control diet (group HpC: MF), a high-salt diet (group HpS: 10% salt MF), or a high-salt, high-fat diet (group HpSF: 10% salt, 26.2% protein, 40% fat, 33.8% carbohydrate MF; soybean oil was added to MF). The diet was administered *ad libitum* beginning at the age of 14 wks, and the animals were maintained on these diets for 16 wks.

Serology

Blood samples were obtained to measure serum gastrin levels by radioimmunoassay (Gastrin-RIA Kit II ; Dainabot Co., Ltd., Tokyo, Japan; human reference interval: <201 ng/L). Radioimmunoassay was performed by the Okayama Medical Center Co., Ltd., (Okayama, Japan).

Histopathology and immunohistochemistry

For each animal, a longitudinal section of the stomach containing both the corpus and antrum was fixed in 10% neutral-buffered formalin, embedded in paraffin, sectioned at 5 μ m, and stained with hematoxylin and eosin and Alcian blue/periodic acid Schiff at pH 2.5 (AB/PAS/pH2.5). The thickness of the mucosa was measured for 10 gastric and 10 pyloric glands per animal on an optical microscope equipped with a scale (40 \times ; Olympus B \times 51; Olympus Optical Co., Ltd., Tokyo, Japan.) Sections of the corpus and antrum were graded for inflammation and atrophic gastritis. The grading system consisted of assigning a score from 0 to 4, with 0 representing normal histology and 4 representing the most severe pathology

Table 1. Grading criteria for gerbil gastric pathology¹⁰⁾

Parameter	Score	Criteria
Inflammation	0	no lymphocytic or granulocytic infiltration
	1	mild mucosal lymphocytic infiltration
	2	moderate mucosal lymphocytic infiltration, some multifocal mucosal lymphoid aggregates
	3	extensive multifocal mucosal lymphoid aggregates
	4	multifocal mucosal and submucosal lymphoid aggregates
Atrophic gastritis	0	parietal cells and glandular architecture preserved
	1	minimal parietal cell loss, glandular architecture preserved
	2	moderate parietal cell loss, glandular architecture preserved
	3	significant parietal cell loss, glandular branching and hyperplasia
	4	significant parietal cell loss, glandular branching and hyperplasia with submucosal glandular herniation

(Table 1)¹⁰⁾. Intestinal metaplasia was confirmed by AB/PAS/pH2.5. In addition, tissue sections were immunostained for proliferating cell nuclear antigen (PCNA) by the polymer-immuno complex method. After deparaffinization and hydration, endogenous peroxidase activity was blocked by incubation with 3% H₂O₂ for 5 min. After a wash in phosphate-buffered saline (PBS), the tissue sections were incubated in 10% fetal bovine serum (FBS) and 0.1% sodium azide in PBS for 5 min. Prior to immunodetection, horseradish peroxidase (HRP; Envision⁺ kit/; Dako, Tokyo, Japan) was conjugated to the primary antibody (mouse monoclonal anti-PCNA; Dako) for 60 min at room temperature. The primary antibody was diluted to 1:100, and the Envision⁺ kit solution was used at the same volume as the primary antibody solution. Normal gerbil serum at a 1:20 of the total volume of the primary antibody solution and Envision + kit solutions were added and incubated for 60 min at room temperature. The sections were then reacted with the primary and secondary antibody solutions for 60 min each at room temperature. After two washes, the slides were developed in 3,3'-diaminobenzidine tetrahydrochloride (20 mg in 100ml Tris-saline buffer containing two drops 30% H₂O₂). Assessment of proliferation was based on the number of PCNA-positive cells per a total of 500 cells in the upper and middle zones. The thickness of the epithelium (from the surface to the proliferation zone) was measured in 20 different areas with an optical microscope

equipped with a scale (Olympus B×51).

Statistical Analysis

All results and mean pathology scores for each type of lesion (inflammation, atrophy) were compared between infected and uninfected animals with the use of nonparametric Mann-Whitney U test. $p < 0.05$ was considered statistically significant. Statistical analysis was performed SPSS Ver.13 (SPSS Inc., Chicago, IL, USA).

RESULTS

Body weight

Mean body weight after 16 wks did not differ significantly between groups. However, group HpS showed the lowest value (Table 2).

Stomach weight

Stomach weight in infected animals was significantly greater than that in group C ($p < 0.05$), and group HpSF showed the lowest value among infected animals ($p < 0.05$) (Table 2).

Serum gastrin

The serum gastrin level was significantly increased in infected animals compared to that in uninfected animals ($p < 0.05$) (Table 2).

Histopathologic observations

Uninfected animals fed the high-salt diet showed decreased mucosal thickness in the corpus

Table 2. Body weight, total dietary intake, stomach weight, and serologic results

Group	No. of gerbils	Antibody titer (OD ₄₅₀) at 14 wks	Body weight (g)	Total intake (g)	Stomach weight (g)/ Body weight 100g	Serum gastrin (ng/ml)
C	5	–	99.5 ± 11.2	764 ± 59	0.72 ± 0.07	136.1 ± 16.8
S	5	–	94.3 ± 7.9	912 ± 103	0.82 ± 0.1	148.4 ± 22.3
HpC	5	0.285 ± 0.172	100.8 ± 14.6	834 ± 70	1.61 ± 0.16*	352.6 ± 50.8*
HpS	5	0.286 ± 0.135	84.1 ± 10.4	865 ± 91	1.64 ± 0.16*	488.2 ± 154.6*
HpSF	5	0.290 ± 0.080	85.3 ± 8.5	791 ± 96	1.33 ± 0.08***†	362.6 ± 73.8*

C: *H. pylori*-uninfected control diet

S: *H. pylori*-uninfected high-salt diet

HpC: *H. pylori*-infected control diet

HpS: *H. pylori*-infected high-salt diet

HpSF: *H. pylori*-infected high-salt, high-fat diet

Values are mean ± SD

* $p < 0.05$ vs. group C; ** $p < 0.05$ vs. group HpC; † $p < 0.05$ vs. HpS

Table 3. Histopathologic observations

Group	No. of gerbils	Thickness (μ m)		Atrophy score		Inflammation Score		Intestinal metaplasia (No. of gerbils)
		Corpus	Antrum	Corpus	Antrum	Corpus	Antrum	
C	5	736 ± 71	257 ± 48	0.2 ± 0.5	0.2 ± 0.4	0	0	0
S	5	522 ± 99*	317 ± 63	0.8 ± 0.4*	1.4 ± 0.9*	0	0.2 ± 0.4	0
HpC	5	1,491 ± 428*	817 ± 307*	3.8 ± 0.4*	4.0*	3.2 ± 0.4*	3.2 ± 0.4*	3
HpS	5	970 ± 282***	821 ± 245*	4.0*	4.0*	4.0***	3.6 ± 0.5***	2
HpSF	5	798 ± 144***†	814 ± 278*	4.0*	4.0*	4.0***	4.0***	2

Values are mean ± SD

* $p < 0.05$ vs. group C; ** $p < 0.05$ vs. group HpC; † $p < 0.05$ vs. group HpS

compared to that in animals fed the control diet (group C: 736 ± 71 μ m; group S: 522 ± 99 μ m; $p < 0.01$) (Table 3), and the thickness of the antral mucosa was significantly greater in group S than in group C (group C: 257 ± 48 μ m; group S: 317 ± 63 μ m; $p < 0.01$). Atrophy scores in the corpus and antrum were significantly higher in group S than in group C (corpus: group C, 0.2 ± 0.5; group S, 0.8 ± 0.4; $p < 0.05$; antrum: group C, 0.2 ± 0.4; group S, 1.4 ± 0.9; $p < 0.05$) (Table 3; Fig 1). In addition, elongation of the gastric pits with slight atrophy was observed in the lesser curvature of the corpus in group S (Fig 2). Inflammation scores did not differ significantly between group C and group S. Severe atrophic gastritis of the corpus characterized by chronic active inflammation was observed in all three groups of infected animals (Table 3; Fig 3 a-c). The corporal mucosa showed loss of parietal cells in all groups. The normal epithelium was replaced by hyperplastic epithelium in group HpC. The antral mucosa also showed inflammation and atrophy comparable to that seen in the corpus (Fig

3 d-f). The overall mucosal thickness was increased in the antrum due to proliferation of the columnar epithelial cells. Mucosal thickness in the corpus was significantly less in group HpS than in group HpC (group HpC: 1491 ± 428 μ m; group HpS: 970 ± 282 μ m; $p < 0.01$) and was the least in group HpSF (798 ± 144 μ m) (Table 3). There was no significant difference in antral mucosal thickness between the three groups. The inflammation score was significantly higher in groups HpS and HpSF than in group HpC (corpus: group HpC, 3.2 ± 0.4; group HpS, 4.0, group HpSF, 4.0; $p < 0.05$) (Table 3). Intestinal metaplasia was found in all groups (group HpC: 3/5; group HpS: 2/5; group HpSF: 2/5) (Table 3), but only one of the HpSF animals showed dysplasia (Fig 4).

Immunohistochemistry

With respect to the PCNA labeling index in the upper zone, there was no significant difference between the uninfected two groups. However, in the middle zone, it was significantly greater in group S

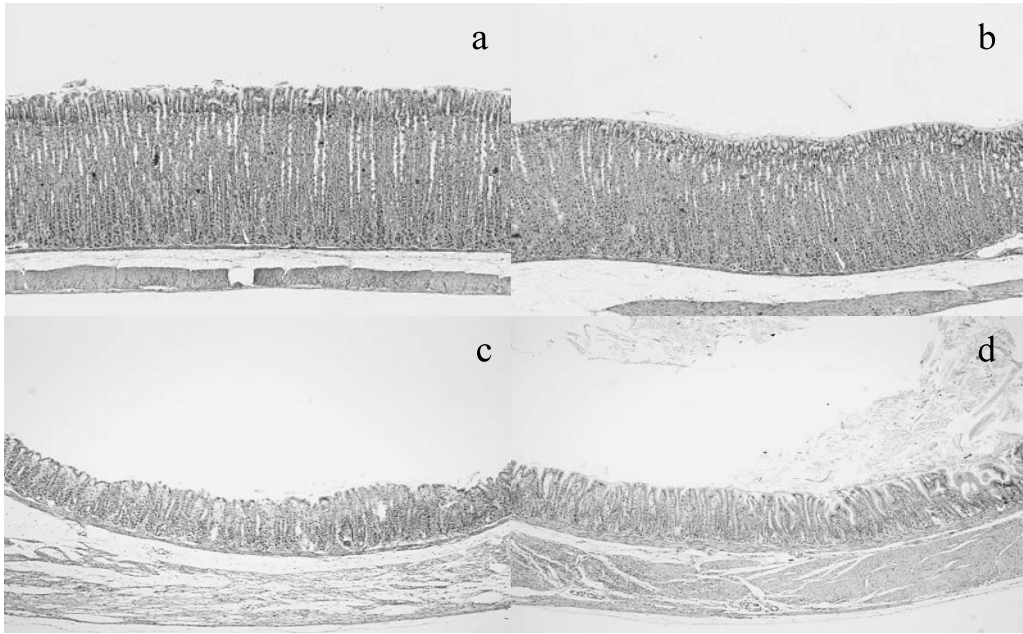


Fig. 1. Images of the corporal and antral mucosae in the greater curvature in *H. pylori*-uninfected animals. a: normal corporal mucosa in the control diet group. b: slight destruction of the epidermal mucosa in the high-salt group. c: normal antral mucosa in the control diet group. d: slight atrophy and elongation of the gastric pits in the high-salt group. Hematoxylin and eosin stain; magnification 40 \times .

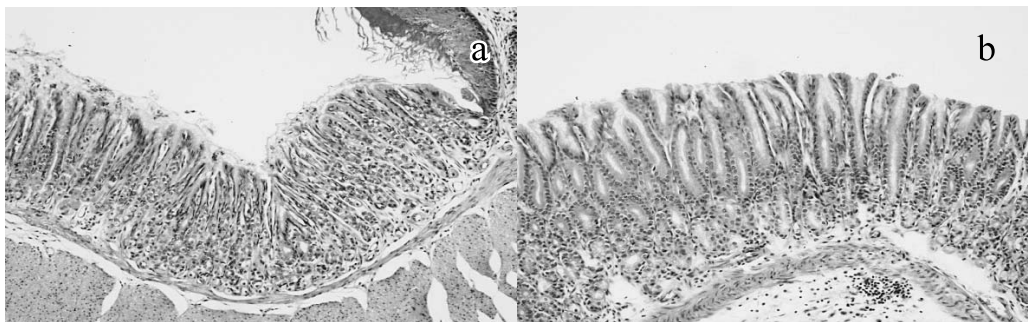


Fig. 2. Images of the corporal mucosa in the lesser curvature in *H. pylori*-uninfected animals. a: normal corporal mucosa in the control diet group. b: elongation of the gastric pits with atrophy in the high-salt group. Hematoxylin and eosin stain; magnification 100 \times .

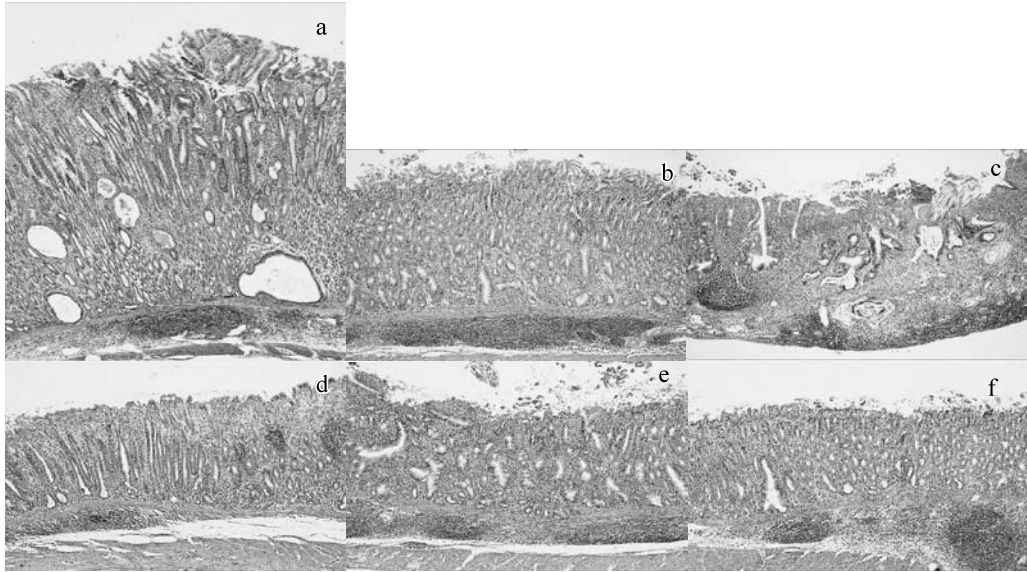


Fig. 3. Images of the corporal and antral mucosae in *H. pylori*-infected animals. a: severe inflammation and atrophy including mucosal and submucosal lymphoid follicles in the control diet group. The normal epithelium is replaced hyperplastic mucosa. b: high-salt group. Hyperplastic epithelium is not seen. c: high-salt, high-fat group. Aberrant glandular branching and dysplasia are seen. Hyperplastic epithelium is not seen. d: inflammatory cell infiltration and severe atrophy in the antrum in the control diet group. The mucosal thickness is increased due to the proliferation of columnar epithelial cells. e: high-salt group. f: high-salt, high-fat group. Hematoxylin and eosin stain; magnification $40\times$.

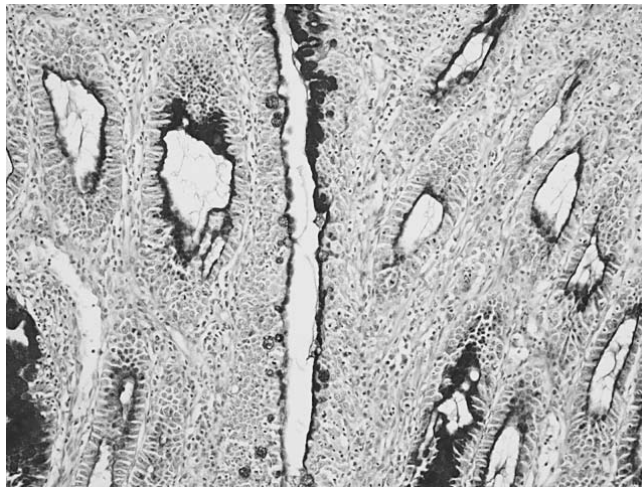


Fig. 4. Image of intestinal metaplasia in *H. pylori*-infected control diet group. Alcian blue/periodic acid-Schiff at pH 2.5 stain; magnification $100\times$.

Table 4. PCNA labeling index and epidermal thickness

Group	No. of gerbils	PCNA labeling index % (cells/500cells)		Epidermal thickness (μm)
		Upper Zone	Middle Zone	
C	5	76.5 \pm 4.1	42.2 \pm 5.8	100 \pm 14.2
S	5	78.2 \pm 2.6	58.5 \pm 10.6*	72.5 \pm 19.5*

Values are mean \pm SD
* $p < 0.05$ vs. group C

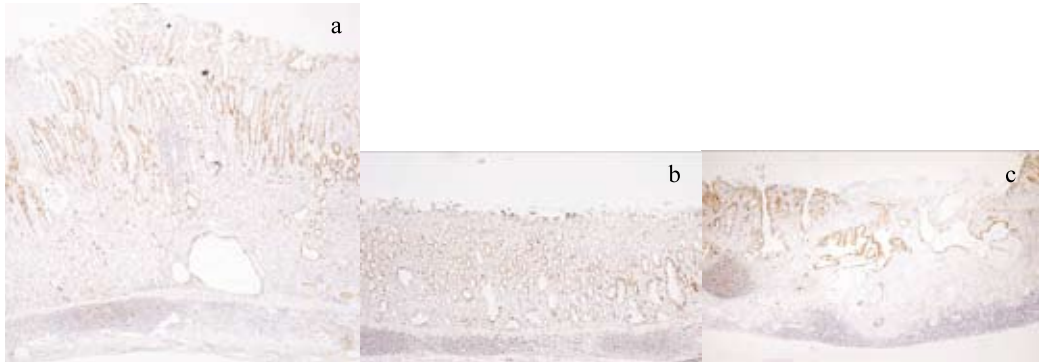


Fig. 5. Images of proliferating cell nuclear antigen immunostaining the corporal mucosa in the greater curvature in *H. pylori*-infected animals. a: a positive cell distribution is seen in the hyperplastic epithelium zone in the control diet group. b: positive cells are distributed throughout the mucosa in the high-salt group. c: positive cells are distributed in areas of aberrant glandular branching and dysplasia in the high-salt, high-fat group. Magnification 40 \times .

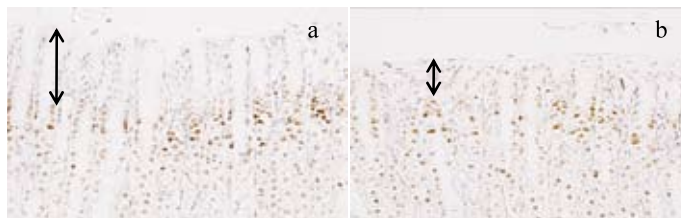


Fig. 6. Images of proliferating cell nuclear antigen immunostaining the corporal mucosa in the greater curvature in *H. pylori*-uninfected animals. a: cellular proliferation in the upper zone and epidermal thickness in the control diet group. b: decreased epidermal thickness in the high-salt group. Magnification 200 \times .

than in group C (group C: 42.2 ± 5.8 ; group S: 58.5 ± 10.6 ; $p=0.01$) (Table 4). We did not examine the labeling index in infected animals, but a positive cell distribution was seen in the epithelium zone in group HpC. The distribution in group HpS was seen through out the entire mucosa (Fig 5). Among uninfected animals, the epidermal thickness in the corpus was less in group S than in group C (group C: $100 \pm 14.2 \mu\text{m}$; group S: $72.5 \pm 19.5 \mu\text{m}$; $p<0.001$) (Table 4; Fig 6).

DISCUSSION

Gastric pathologic changes were observed in *H. pylori*-positive and -negative gerbils fed a high-salt diet for 16 wks. Uninfected animals fed a high-salt diet showed elongation of the gastric pits in the lesser curvature, cellular proliferation in the middle

zone of the corpus mucosa, and decreased epidermal thickness in the greater curvature. In the lesser curvature, elongation of the gastric pits was seen in the place of parietal, chief, and mucous cells, and a hyperplastic columnar epithelium was observed. In addition, severe inflammation was not observed in the high-salt group. Bergin *et al.*¹⁰⁾ reported that a high-salt diet (2.5%) in uninfected gerbils resulted in significant histologic changes in the corpus compared to controls (0.25% salt), and a high-salt diet induced cellular proliferation, as indicated by elongation of the gastric pits. In addition, in contrast to *H. pylori*-infected animals, uninfected animals on a high-salt diet did not show mucosal or submucosal inflammation, suggesting that atrophic gastritis is not a necessary sequela to inflammation and may be induced independently by other factors. Fox *et*

*al.*¹¹⁾ fed C57BL/6 mice a high-salt diet (7.5%) and showed elongation of the gastric pits, reduction of the parietal zone, and significantly increased 5-bromo-2deoxyuridine (BrdU) incorporation in the corpus and antrum compared to gerbils fed a normal diet. They showed that elongation of the gastric pits was not associated with an overall increase in mucosal thickness but instead occurred in tandem with a loss of parietal cells lining the underlying glands. We suggest that excessive salt intake may cause atrophy of the gastric mucosa without inducing inflammatory cytokines. A high-salt diet induces high osmotic pressure and may increase the permeability of the membrane, which can injure the epithelium. Damage of the epidermal mucosa then stimulates proliferation of corpus mucosal cells, resulting in a higher PCNA labeling index in the high-salt group than in the control group. However, the damage is chronic, and the epidermal mucosa can not maintain cell proliferation. Gastrin and transforming growth factor α have been implicated in the influence of cellular turnover and differentiation¹²⁾. In the present study, there was no significant difference in gastrin levels between the control and high-salt groups. It is possible that excessive salt damages the gastric mucosa directly, causing cellular turnover and mutation.

All *H. pylori*-infected animals showed severe atrophic gastritis and intestinal metaplasia. Inflammation of the corpus mucosa was severe in the high-salt group compared to the control diet group. Gastric glands in infected animals fed the control diet were not present, and these animals showed a hyperplastic epithelium; a decrease of the corpus membrane with a decrease of parietal cells was observed in the high-salt group. Tatematsu *et al.*¹³⁾ reported that high salt administration significantly enhances gastric carcinogenesis in *N*-methyl-*N'*-nitro-*N*-nitrosourea-treated rats and that the presence of NaCl possibly decreases the viscosity of the gastric mucus, reduces the

protective mucous barrier in a manner similar to that of surface active agents, and allows direct contact of carcinogens with the gastric mucosa. It has been reported that continuous salt intake (2.5%-10%) promotes gastric carcinogenesis by exacerbating gastritis induced by *H. pylori* infection¹⁴⁾. Studies of the effect of salt on *H. pylori* have shown that high salt concentrations stimulate increased expression of *H. pylori* cytotoxin-associated gene A (*CagA*), which in turn leads to an increase in CagA protein translocated into gastric epithelial cells and an enhanced ability of *H. pylori* to alter gastric epithelial cell function¹⁵⁾. Sun *et al.*¹⁶⁾ reported that *H. pylori* vacuolating cytotoxin A (VacA) decreases the viability of VacA-treated human gastric epithelial cells, and this effect can be enhanced by NaCl. NaCl also affects the production of proinflammatory cytokines induced by VacA, in particular, interleukin-1 (IL-1), IL-6, and tumor necrosis factor α levels are higher in *H. pylori*-infected animals fed a 5 g/kg NaCl diet. Another study of the effect of a high-salt diet (8%) on the progression of intestinal metaplasia in mice showed that high salt induces epithelial cell proliferation and apoptosis and alters cell types¹⁷⁾. These authors suggested that a high-salt diet stimulates the turnover of intestinal metaplastic epithelial cells.

Our present results and taken together with results of other studies suggest that excessive salt in the diet may promote destruction of the mucus barrier and decrease mucus viscosity, facilitating access of *H. pylori* to the mucosa. Excessive salt also promotes *H. pylori* activity and the induction of inflammatory cytokines. We suggest that salt affects *H. pylori*-positive and -negative mucosae differently; salt induces atrophy of the gastric mucosa in the absence of infection. However, in the presence of *H. pylori* infection, the effects of salt may increase CagA or inflammatory cytokines. Other interesting observations in the present study included a reduction of the corpus mucosa and the finding of

dysplasia in the high-salt, high-fat group. Similar structural characteristics between the high-salt group and high-salt, high-fat group were observed. However, we speculate that fat extends the effect of salt in the stomach such that permeability of the membrane and damage to the mucosa layer are increased. The gastric membrane in the high-salt, high-fat group responds to this with abnormal cell turnover.

In conclusion, results of the present study suggest that excessive salt intake promotes corpus atrophic gastritis, and high fat intake may increase the effect of salt. Thus, intake of salt and fat should be limited to prevent atrophic gastritis and gastric cancer.

REFERENCES

- 1) IARC: World cancer report. Lyon, France, IARC Press. 2003, pp 194
- 2) Tsugane S, Sasazuki S: Diet and the risk of gastric cancer: review of epidemiological evidence. *Gastric cancer* 10 : 75-83, 2007
- 3) Haenszel W, Kurihara M, Segi M, Lee RK: Stomach cancer among Japanese in Hawaii. *J Natl Cancer Inst* 49 : 969-988, 1972
- 4) Tajima K, Tominaga S: Dietary habits and gastrointestinal cancers: a comparative case-control study of stomach and large intestinal cancers in Nagoya, Japan. *Jpn J Cancer Res* 76 : 705-716, 1985
- 5) Tsugane S, Akabane M, Inami T, Matsushima S, Ishibashi T, Ichinowatari Y, Miyajima Y, Watanabe S: Urinary salt excretion and stomach cancer mortality among four Japanese populations. *Cancer Causes Control* 2 : 165-168, 1991
- 6) Hirohata T, Kono S: Diet/nutrition and stomach cancer in Japan. *Int J Cancer* 10 : 34-36, 1997
- 7) http://www.who.int/dietphysicalactivity/publications/trs916/en/gsfao_cancer.pdf (2010.1.7)
- 8) <http://www.mhlw.go.jp/houdou/2008/12/h1225-5.html> (2010.1.7).
- 9) Hirayama F, Takagi S, Kusuhara H, Iwao E, Yokoyama Y, Ikeda Y: Induction of gastric ulcer and intestinal metaplasia in Mongolian gerbils infected with *Helicobacter pylori*. *J Gastroenterol* 31 : 755-757, 1996
- 10) Bergin IL, Sheppard BJ, Fox JG: *Helicobacter pylori* infection and high dietary salt independently induce atrophic gastritis and intestinal metaplasia in commercially available outbred Mongolian gerbils. *Dig Dis Sci* 48 : 475-485, 2003
- 11) Fox JG, Dangler CA, Taylor NS, King A, Koh TJ, Wang TC: High-salt diet induces gastric epithelial hyperplasia and parietal cell loss, and enhances *Helicobacter pylori* colonization in C57BL/6 mice. *Cancer Res* 59 : 4823-4828, 1999
- 12) Nozaki K, Shimizu N, Inada K, Tsukamoto T, Inoue M, Kumagai T, Sugiyama A, Mizoshita T, Kaminishi M, Tatematsu M.: Synergistic promoting effects of *Helicobacter pylori* infection and high-salt diet on gastric carcinogenesis in Mongolian gerbils. *Jpn J Cancer Res* 93 : 1083-1089, 2002
- 13) Tatematsu M, Takahashi M, Fukushima S, Hananouchi M, Shirai T: Effects in rats of sodium chloride on experimental gastric cancers induced by N-methyl-N-nitro-N-nitrosoguanidine or 4-nitroquinoline-1-oxide. *J Natl Cancer Inst* 55 : 101-106, 1975
- 14) Kato S, Tsukamoto T, Mizoshita T: High salt diets dose-dependently promote gastric chemical carcinogenesis in *Helicobacter pylori*-infected Mongolian gerbils associated with a shift in mucin production from glandular to surface mucous cells. *Int J Cancer* 119 : 1558-1566, 2006
- 15) Loh JT, Torres VJ, Cover TL: Regulation of *Helicobacter pylori* *cagA* expression in response to salt. *Cancer Res* 67 : 4709-4715, 2007
- 16) Sun J, Aoki K, Zheng JX, Su BZ, Ouyang XH, Misumi J: Effect of NaCl and *Helicobacter pylori* vacuolating cytotoxin on cytokine expression and viability. *World J Gastroenterol* 12 : 2174-2180, 2006
- 17) Xiao F, Crissey MA, Lynch JP, Kaestner KH, Silberg DG, Suh E: Intestinal metaplasia with a high salt diet induces epithelial proliferation and alters cell composition in the gastric mucosa of mice. *Cancer Biol Ther* 4 : 669-675, 2005