

## A case report of sigmoid colon cancer during pregnancy

Yang-Sil CHANG<sup>1)</sup>, Tsuyoshi ISHIDA<sup>1)</sup>, Yuichiro NAKAI<sup>1)</sup>, Norichika USHIODA<sup>1)</sup>,  
Shoji KAKU<sup>1)</sup>, Takafumi NAKAMURA<sup>1)</sup>, Yasuo OKA<sup>2)</sup>, Kazuki YAMASHITA<sup>2)</sup>,  
Koichiro SHIMOYA<sup>1)</sup>

*1) Department of Obstetrics and Gynecology, 2) Department of Digestive Surgery, Kawasaki Medical School,  
577 Matsushima Kurashiki 701-0192, Japan*

**ABSTRACT** Carcinoma of the colon-rectum in pregnancy is very rare. The prognosis of pregnant women complicated with colon-rectal cancer is poor because the diagnosis of this cancer is often made at an advanced stage. This report is on a case of sigmoid colon cancer in a pregnant woman in the second trimester.

*(Accepted on August 25, 2010)*

Key words : **Sigmoid colon cancer, Pregnancy, Case report**

### INTRODUCTION

Carcinoma of the colon-rectum in pregnancy is very rare and the incidence is reported in 0.002% of all pregnancies<sup>1)</sup>. It has been reported that the incidence of complications with colon-rectal cancer is approximately 1 per 150,000 deliveries in the California Cancer Registry<sup>2)</sup>. The prognosis of pregnant women complicated with colon-rectal cancer is poor because the diagnosis of this cancer is often made at an advanced stage<sup>3,4)</sup>. Most cases of colon-rectal cancer are discovered in late pregnancy and more than 80% of the patients have rectal carcinoma<sup>4)</sup>. The prognoses in pregnant patients by stage have no difference from those in non-pregnant patients with colorectal carcinoma<sup>4)</sup>. We will report on a case of sigmoid colon cancer in a pregnant woman, discovered in the second trimester.

### CASE REPORT

A 34-year-old primigravida was referred to our department from a private clinic at 21 weeks' gestation with a left ovarian enlargement and elevated CEA, CA19-9 and CA125. It was found that the serum levels of CEA, CA19-9, and CA125 were 332ng/ml, 11160U/ml and 110.5U/ml respectively. The patient had no significant medical or surgical history. Her paternal grandfather had gastric cancer and her maternal grandfather had colon cancer. She had a gynecological checkup in a private clinic early in the pregnancy and the course of her pregnancy was uneventful apart from the left ovarian enlargement. The vaginal ultrasonography showed a 6.6×4.4cm (approx.) hypoechoic lesion of the left ovarian tumor (Fig. 1). The MRI showed both ovarian tumors and multiple metastatic liver tumors at 23 weeks' gestation (Fig. 2, 3).

The patient was admitted at 24 weeks' gestation.

---

Corresponding author  
Koichiro Shimoya  
Department of Obstetrics and Gynecology, Kawasaki  
Medical School, 577 Matsushima Kurashiki, 701-0192,  
Japan

Phone : 81 86 462 1111  
Fax : 81 86 462 1199  
E-mail : shimoya@med.kawasaki-m.ac.jp

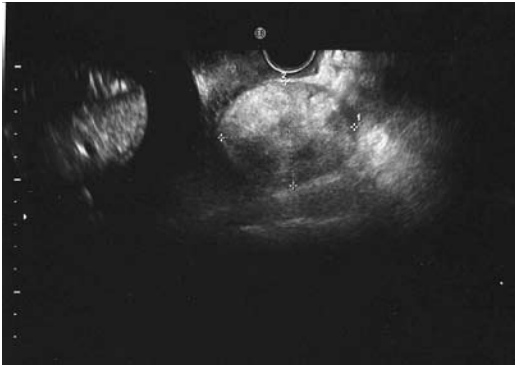


Fig. 1. Ultrasound sonography of metastatic ovarian tumor  
The vaginal ultrasonography demonstrated a  $6.6 \times 4.4$ cm (approx.) hypoechoic lesion of the left ovarian tumor.

The physical examination on admission was normal and fetal growth was consistent with gestational age. AST (40IU/ml) and LDH (835IU/ml) were elevated. The serum levels of CEA, CA19-9, and CA125 were 369.4ng/ml, 7730U/ml and 141U/ml respectively. Because of a positive fecal occult blood test, an upper gastrointestinal endoscopy and a lower gastrointestinal endoscopy were performed. The colonoscopy revealed, at 20cm depth, an ulcerated mass in the sigmoid colon (Fig. 4). Biopsies were taken and the histopathological examination showed adenocarcinoma of the sigmoid colon. The ovarian

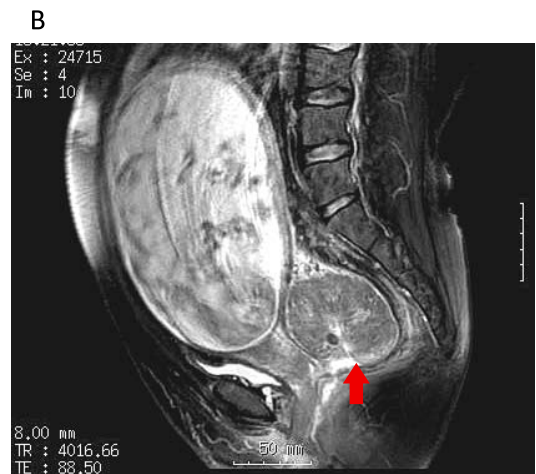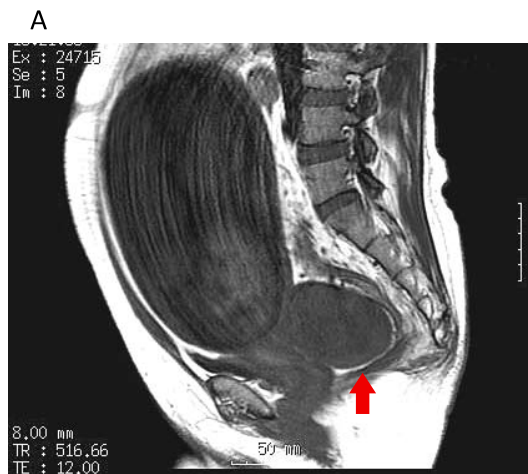


Fig. 2. MRI of the pelvis (A: T1 weighted, B: T2 weighted)  
The MRI showed left ovarian tumor at 23 weeks' gestation.

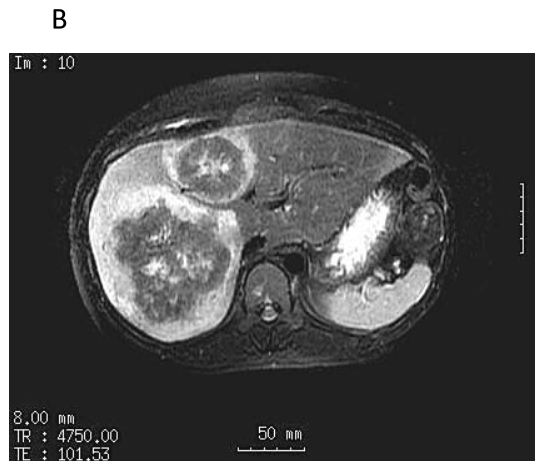
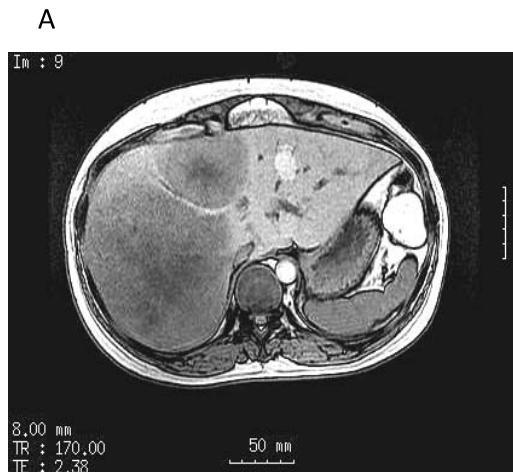
Fig. 3. MRI of the liver (A: T1 weighted, B: T2 weighted)  
The MRI revealed multiple metastatic liver tumors at 23 weeks' gestation.

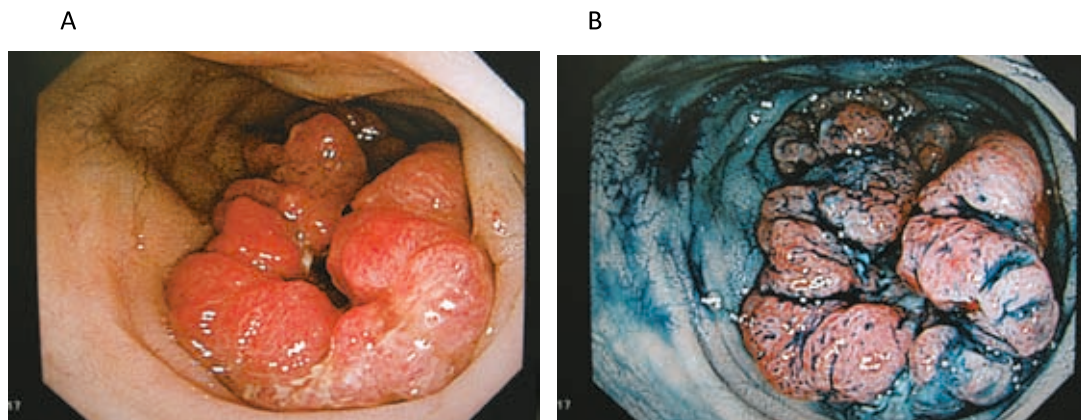


Fig. 4. The findings of colonoscopy

The colonoscopy revealed an ulcerated mass in the sigmoid colon at 20cm depth. The histopathological examination showed adenocarcinoma of sigmoid colon.

tumors and liver tumors were found to be metastatic tumors of sigmoid colon cancer. It was diagnosed the fourth stage of the sigmoid colon cancer.

After betamethasone administration for fetal lung maturation, a cesarean section was performed at 27week's gestation and a 973g healthy female infant was born. At the same time, bilateral-salpingo-oophorectomy and Hartmann's procedure were performed. Seven days after the operation FOLFOX therapy (oxaliplatin, bolus and infusional 5-FU, and leucovorin) started for the treatment of sigmoid colon cancer, but it was stopped after 5months because of the patient's allergies. Following this, FOLFIRI therapy (irinotecan, bolus and infusional 5-FU, and leucovorin) with bevacizumab started for the second line chemotherapy. However, it was stopped after 6 months because of disease progression. The patient had developed liver metastases, lung metastases and bone metastases approximately one year after her operation and she had sequential therapy.

## DISCUSSION

In 1928, Evers reported the first case of large intestine carcinoma during pregnancy<sup>5)</sup>. Colorectal carcinoma is common after middle-age, but 2-6% of big intestine tumors are found before the age of 40<sup>5)</sup>.

CEA is a useful tumor marker of colon cancer. It may be elevated during normal pregnancy, however its baseline values may be useful<sup>8)</sup>. Pregnant patients with advanced colorectal carcinomas have a poor prognosis<sup>4)</sup>. Metastatic reflection of colon carcinoma to the ovaries is found in approximately 25% of pregnant women with this condition<sup>6)</sup>. Dahling et al. reported patients with pregnancy-associated colorectal carcinoma tended to undergo cesarean section (OR: 1.9) and to develop puerperal infections (OR: 2.8)<sup>7)</sup>. In addition, there was no evidence that pregnancy affected the survival rate compared with non-pregnant women<sup>7)</sup>.

The early symptoms of patients with colorectal carcinoma are nausea, vomiting, constipation, distension, etc. Because these symptoms are similar to those of normal pregnant women, it is difficult to diagnose colorectal carcinoma during pregnancy. If a colorectal carcinoma is suspected, a fecal occult blood test, digital rectal examination, and flexible colonoscopy should be undertaken as soon as possible. After the diagnosis of colorectal carcinoma, the pregnant woman should be treated according to the same general guidelines of non-pregnant woman. However, if it is found during later pregnancy, delayed treatment may be allowed in consideration of fetus maturation.

In this case we discussed the chemotherapy of colorectal cancer during pregnancy. Adjuvant chemotherapy and radiation have limited roles in the therapy of pregnant women with colorectal carcinoma, especially with advanced tumors<sup>4)</sup>. The colonoscopy revealed an ulcerated mass in the sigmoid colon. The mass might obstruct the tract during pregnancy. We therefore opted for that the resection of the colon cancer and metastatic ovarian tumor immediately.

#### REFERENCES

- 1) Shushan A, Stemmer SM, Reubinoff BE, Eid A, Weinstein D: Carcinoma of the colon during pregnancy. *Obstet Gynecol Surv.* 47:222-225. 1992
- 2) Smith LH, Danielsen B, Allen ME, Cress R: Cancer associated with obstetric delivery: results of linkage with the California cancer registry. *Am J Obstet Gynecol* 189:1128-1135. 2003
- 3) Colecchia G, Nardi M: Colorectal cancer in pregnancy. A case report. *G Chir* 20:159-161. 1999
- 4) Walsh C, Fazio VW. Cancer of the colon, rectum, and anus during pregnancy. The surgeon's perspective. *Gastroenterol Clin North Am* 27:257-267. 1998
- 5) Vitoratos N, Salamalekis E, Makrakis E, Creatsas G: Sigmoid colon cancer during pregnancy. *Eur J Obstet Gynecol Reprod Biol* 5:104:70-72. 2002
- 6) Heres P, Wiltink J, Cuesta MA, Burger CW, van Groeningen CJ, Meijer S: Colon carcinoma during pregnancy: a lethal coincidence. *Eur J Obstet Gynecol Reprod Biol* 48:149-152. 1993
- 7) Dahling MT, Xing G, Cress R, Danielsen B, Smith LH: Pregnancy-associated colon and rectal cancer: perinatal and cancer outcomes. *J Matern Fetal Neonatal Med* 22:204-211. 2009
- 8) Minter A, Malik R, Ledbetter L, Winokur TS, Hawn MT, Saif MW: Colon cancer in pregnancy. *Cancer Control* 12:196-202. 2005