

〈Original Article〉

Skin Tube Reconstruction for Esophageal Defects due to Postoperative Complications: Applying a skin flap in esophageal resection and reconstruction

Tomoki YAMATSUJI, Kaori SHIGEMITSU, Munenori TAKAOKA, Takurou YUKAWA, Masakazu YOSHIDA, Ryutaro ISODA, Sayaka SAKURAI, Takuya FUKAZAWA, Naomasa ISHIDA, Jiro HAYASHI, Kazuhiro YOSHIDA, Yoko HIRABAYASHI, Atsushi URAKAMI, Kazutaka NAKASHIMA, Ichiro MORITA, Minoru HAISA, Yoshio NAOMOTO

*Department of General Surgery, Kawasaki Medical School,
2-1-80 Nakasange, Kitaku, Okayama 700-8505, Japan*

ABSTRACT Numerous improvements and advances in operational methods and techniques have occurred in the area of reconstruction for esophageal cancer. Patients with thoracic esophageal cancer who have previously had a gastrectomy usually undergo reconstruction using the colon and small intestine. The incidence of organ necrosis is not necessarily low after reconstruction with those organs. Generally, the main types of skin flaps and musculocutaneous flaps used for cervical and other esophageal reconstructions are deltopectoral (DP) flaps, pedicled musculocutaneous latissimus dorsi flaps and free anteriolateral thigh flaps. This kind of reconstruction is low invasive, relatively simple, and also causes very few fatal post-operative complications. Therefore, it is considered to be an effective reconstruction choice for the following types of patients: poor risk patients, patients whose gastrointestinal (GI) tract cannot be used for their reconstruction for some reason, and patients having a second reconstruction due to complications caused by organ necrosis after their first GI tract reconstruction.

doi:10.11482/KMJ-E41(1)23 (Accepted on June 13, 2015)

Key words : Esophageal cancer, Skin flap, Reconstruction

INTRODUCTION

Improvements and advances in operational methods and techniques have occurred in the area of reconstruction for esophageal cancer. In recent years, elder patients and cases with cardiovascular

and/or metabolic complications, such as diabetes mellitus, are increasing. Those patients tend to frequently suffer from postoperative complications¹⁾. Salvage operations after chemoradiation therapy are increasing as well. In many of those cases, a

Corresponding author :
Yoshio Naomoto

Department of General Surgery, Kawasaki Medical
School, 2-1-80 Nakasange, Kitaku, Okayama 700-8505,
Japan

Phone : 81 86 225 2111

Fax : 81 86 232 8343

E-mail: ynaomoto@med.kawasaki-m.ac.jp

presternal route reconstruction is often performed for the sake of safety, but the anastomotic leakage rate can be higher than in other routes²⁾. Additional operations are frequently required to repair various kinds of problems. Under the above circumstances, reconstruction involving a skin flap can be an option to choose for the repair.

The cases are either patients who could not have reconstruction using the GI tract for some reason, or patients whose reconstructed organ became necrotic. Using a skin flap is considered to be effective for those cases or as a secondary reconstruction to treat patients with complications. In this report, we introduce our original techniques and ideas.

INDICATIONS & METHODS

Indications

The indications are as follows: major leakage from an esophagogastrostomy which used a presternal route reconstruction, necrosis in the esophago-intestinal anastomosis site, a secondary reconstruction for circular necrosis of the reconstructed organ or closing an intractable fistula caused by anastomotic leakage after esophageal reconstruction.

Short skin role with a deltopectoral (DP) flap

Deltopectoral flaps were reportedly first used for pharyngo-cervical esophageal reconstruction by creating a cylinder shaped skin tube³⁾. This procedure was originally suggested to be done as a two stage operation, but below is our slightly different method.

Seven to 10 days prior to the operation, create a surgically delayed flap and suture it back to the skin (Fig. 1). This can prevent a decrease in blood flow during the operation. The DP flap gets its blood supply from both perforating branches of the internal thoracic and thoracoacromial vessels. Since the perforating branches in the second intercostal are normally thought to be the most developed, to

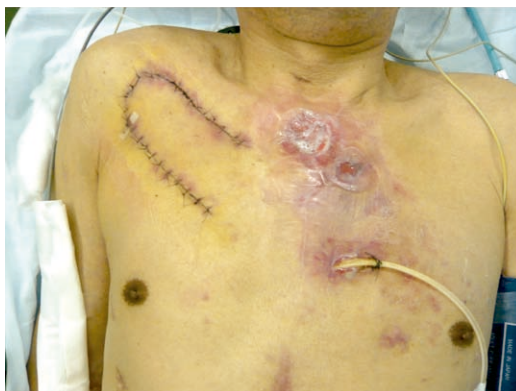

Fig. 1. Delayed deltopectoral skin flap

creation a skin flap using the branches as a pedicle is adequate.

If reconstruction is planned in the cervical area, it is recommended to create a DP cutaneous flap that extends close to the shoulder. In addition, since cases in which reconstruction will be performed using a skin flap often tend to be high-risk ones, we consider the extended flap method to be more effective.

We recommend to evaluate the blood flow by checking the color of the skin flap and the amount of bleeding and suture the defect in two layers with 4-0 absorbable monofilament sutures (Figs. 2, 3a, and 3b). The final 2-3 stitches should be in a Gambee suture pattern (Fig. 3c). If there is no tension in the skin defect in the donor site, it can be closed by primary suture (Figs. 4, 5 and 6). If there

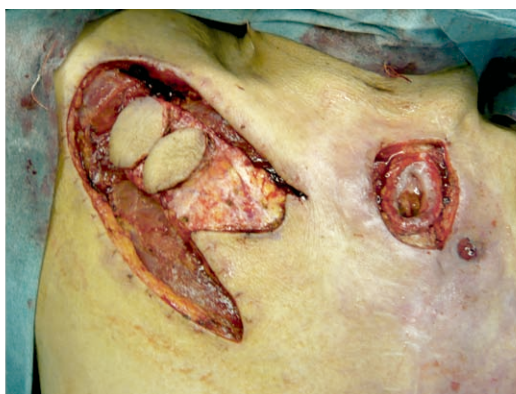

Fig. 2. Skin flap and fistula

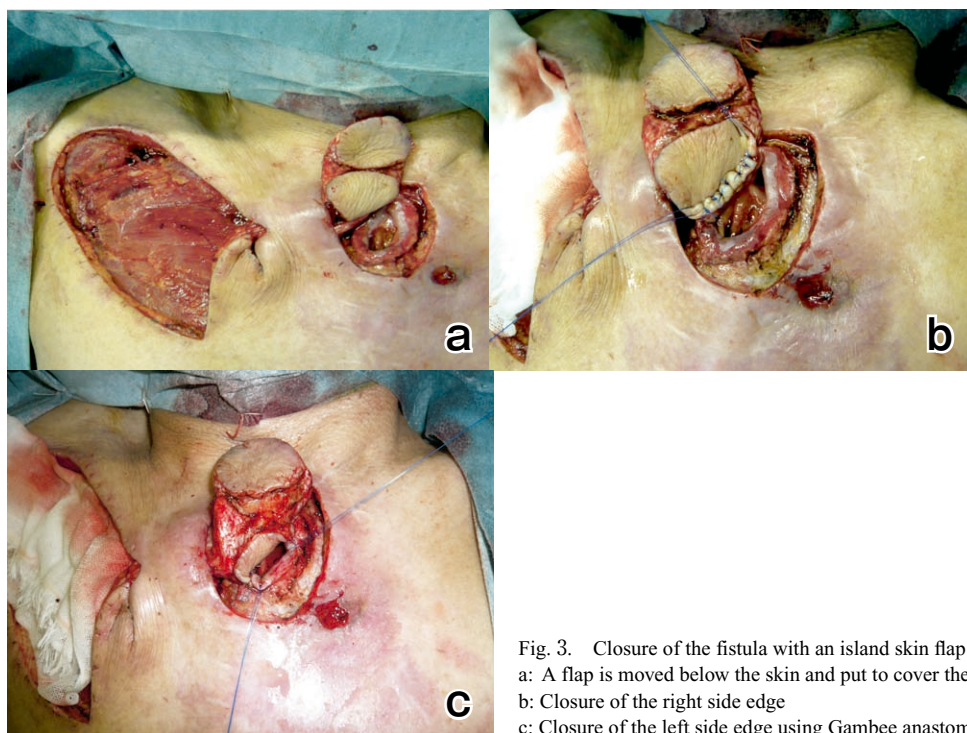


Fig. 3. Closure of the fistula with an island skin flap:
a: A flap is moved below the skin and put to cover the fistula
b: Closure of the right side edge
c: Closure of the left side edge using Gambee anastomosis

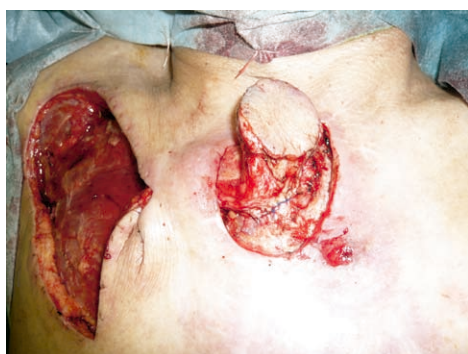

Fig. 4. Completed closure of the fistula

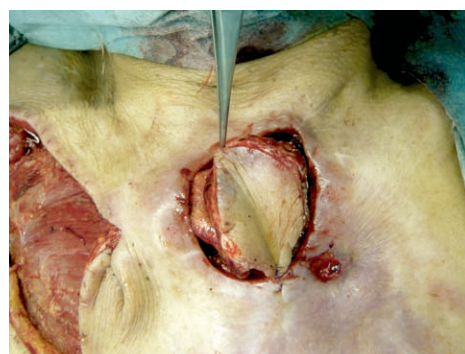

Fig. 5. Closure of the skin defect with an island skin flap

is tension, it is possible to use a skin mesh from the femoral area to close the opening.

Long skin role

When reconstructed organs lapse into severe ischemia or extensive necrosis, long skin role is one of the options for the next reconstruction.

A patient, eighty years old male had reconstruction with the ascending colon after an esophagectomy because of a gastrectomy. A reconstruction with

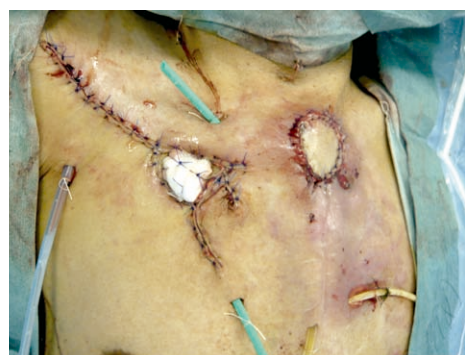

Fig. 6. Completed appearance

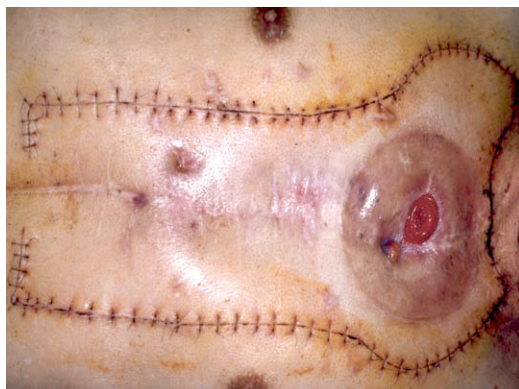

Fig. 7. Long skin role: delayed flap and design

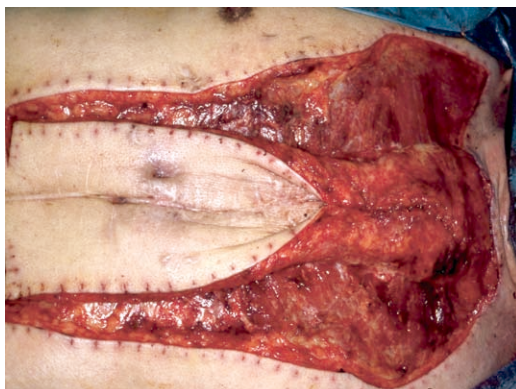


Fig. 8. Long skin role formation

a long skin role was scheduled after the colon necrotized. A longitudinal delayed skin flap was made in the anterior chest wall. The skin flap was carefully made to avoid injuries to the skin segment blood supply, which is delivered from vessels perforated from internal mammary vessels (Fig. 7). The long skin role was made with a one week interval. The esophagostomy was covered with skin role in the oral region, and an anastomosis between the skin role and jejunum was made in the anal region (Fig. 8). Finally, the long skin role was covered with a mesh skin graft (Fig. 9). The patient could eat usual food after the reconstruction with a long skin role.

Post-operative management

Avoiding pressure on the wounds is quite important for the wound healing. The sutures are removed 10 to 14 days after the operation, and a fluoroscopy is performed on the 14th day. After that, the patient can begin oral intake.

DISCUSSION

Numerous improvements and advances in operational methods and techniques have occurred in the area of reconstruction for esophageal cancer⁴⁾. Generally, the types of skin flaps and musculocutaneous flaps used for cervical esophagus reconstruction are DP flaps, pectoralis major

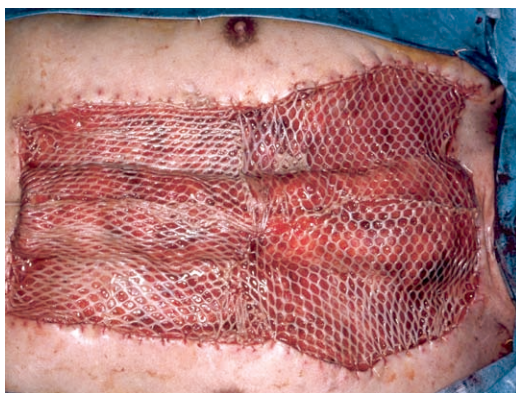

Fig. 9. Long skin role covered with mesh skin grafts

muscle-musculocutaneous flaps and latissimus dorsi muscle- musculocutaneous flaps used as a pedicle flap⁵⁾. Among free graft skin flaps that combine vessel anastomosis, there are forearm cutaneous flaps and rectus abdominis muscle-musculocutaneous flaps⁶⁾. Intestinal free grafts using vessel anastomosis have been gaining acceptance along with the progress of more delicate operative techniques, therefore reconstruction using a skin flap or a musculocutaneous flap has not been chosen as the primary option as often recently⁷⁾. However, this reconstruction is low invasive, can be performed relatively simply, and also causes very few fatal post-operative complications. Therefore, it is considered to be an effective reconstruction option.

Esophageal reconstruction using a skin flap has a long history and it was often used for cervical esophageal reconstructions⁸⁾. However, since cervical esophageal reconstruction was improved by using the jejunum in microsurgery, the skin flap method has rarely been performed as a reconstruction. Despite a decline in the number of operations using DP flaps for esophageal reconstruction, the method reported in this paper is still meaningful even now. It is low invasive and does not causing any major post-operative problems, thus it can be performed on poor risk patients relatively safely⁹⁾.

When we perform an esophageal reconstruction through the presternal route, we consider and choose skin flap reconstruction to reduce the possibility of other problems arising. We usually create a subcutaneous space by sacrificing the perforating branches of the internal thoracic vessels (both artery and vein) on the left side, and preserve the right side. When reconstruction with a skin flap is necessary, it is normal to use a DP flap on the right side.

This method is relatively simple and can be performed safely by surgeons who can design a skin flap for the defective part and who have acquired enough operating skill. It's a very effective method to use even nowadays since the number of salvage operations and poor risk cases have been increasing.

Eleven cases have been performed at our hospital since 2002. There were 4 cases of light anastomotic leakage in the suture where the skin flap and GI tract merged after the operation. However, they were conservatively curable. All the cases showed satisfactory progress, oral intake became possible and all of the patients could eventually be discharged from the hospital.

CONCLUSIONS

Although the indications for this method are quite limited because microsurgery has advanced considerably, using a flap is a skill that surgeons specializing in the esophagus should acquire due to the procedure's low invasiveness and the low occurrence of major complications.

REFERENCES

- 1) Wormuth JK, Heitmiller RF : Esophageal conduit necrosis. *Thorac Surg Clin* 16: 11-22, 2006
- 2) Davis PA, Law S, Wong J : Colonic interposition after esophagectomy for cancer. *Arch Surg* 138: 303-308, 2003
- 3) Bakamjian VY : Total reconstruction of pharynx with medially based deltopectoral skin flap. *N Y State J Med*. 68: 2771-2778, 1968
- 4) Ascoti AJ(1), Hofstetter WL, Miller MJ, Rice DC, Swisher SG, Vaporciyan AA, Roth JA, Putnam JB, Smythe WR, Feig BW, Mansfield PF, Pisters PW, Torres MT, Walsh GL : Long-segment, supercharged, pedicled jejunal flap for total esophageal reconstruction. *J Thorac Cardiovasc Surg* 130: 1391-1398, 2005
- 5) Yu P, Robb GL: Pharyngoesophageal reconstruction with the anterolateral thigh flap: a clinical and functional outcomes study. *Plast Reconstr Surg* 116: 1845-1855, 2005
- 6) Castillo MH, Peoples JB, Machicao CN, Singhal PK : The lateral island trapezius myocutaneous flap for circumferential reconstruction of hypopharynx and cervical esophagus. *Dig Surg* 18: 93-97, 2001
- 7) Okazaki M, Asato H, Takushima A, Nakatsuka T, Ueda K, Harii K : Secondary reconstruction of failed esophageal reconstruction. *Ann Plast Surg* 54: 530-537, 2005
- 8) Carlson GW, Schusterman MA, Guillaumondegui OM : Total reconstruction of the hypopharynx and cervical esophagus: a 20-year experience. *Ann Plast Surg* 29: 408-412, 1992
- 9) Hamai Y, Hihara J, Emi m, Tanabe K, Miyamoto Y, Okada M: Skin tube reconstruction for esophageal defect due to postoperative complication. *Ann Thorac Surg* 87:1605-1607, 2009

