

〈Case Report〉

## Cellulitis caused by *Streptococcus pyogenes* at the Bacille Calmette-Guérin vaccination site: A case report

Eisuke KONDO<sup>1)</sup>, Takaaki TANAKA<sup>2)</sup>, Takashi NAKANO<sup>2)</sup>, Kazunobu OUCHI<sup>1)</sup>

1) Department of Pediatrics, Kawasaki Medical School,

2) Kawasaki Medical School, Department of Pediatrics, Kawasaki Medical School General Medical Center

**ABSTRACT** Recently, the number of reports on skin manifestations, including tuberculids, developing as adverse reactions to the Bacille Calmette-Guérin (BCG) vaccine has increased in Japan. We encountered a case in which an infant developed cellulitis at the vaccination site. The patient was a girl who received the BCG vaccine 5 months after birth. Two months after vaccination, she developed a fever of 39°C, and redness and swelling spread to the entire left upper arm. After being treated with oral cefditoren pivoxil, she was referred to our hospital and received treatment with intravenous sulbactam/ampicillin. *Streptococcus pyogenes* was detected in a culture of the vaccination scars, and the reaction was very likely caused by pathogenic bacteria. There has been no previous report on a patient developing cellulitis following BCG vaccination caused by *S. pyogenes* at the vaccination site. Here, we describe such a case with a literature review. doi:10.11482/KMJ-E44(1)27 (Accepted on March 27, 2018)

Key words : Bacille Calmette-Guérin vaccine, Adverse reaction, Cellulitis, *Streptococcus pyogenes*

### INTRODUCTION

The Bacille Calmette-Guérin (BCG) vaccine is a live vaccine containing an attenuated *Mycobacterium bovis* strain that had been subcultured several times by Albert Calmette and Camille Guérin of the Pasteur Institute in France. The BCG vaccine used in Japan (Tokyo 172) is reported to have immunogenicity as high as that of vaccines used in other countries, but the strain is attenuated to considerably reduce the risk of adverse reactions<sup>1)</sup>. Furthermore, the percutaneous tube needle method, which is a vaccination method unique to Japan, is known to cause fewer local

reactions compared to those caused by conventional intracutaneous vaccinations.

We encountered a case in which a 5-month-old infant received the BCG vaccination and developed cellulitis at the BCG vaccination site on the left upper arm 2 months later. *Streptococcus pyogenes* was isolated from the local lesion site. Reports of cellulitis as an adverse reaction following BCG vaccination are limited. As there has been no previous report of such a case caused by *S. pyogenes*, we herein report our case with a review of the relevant literature.

---

Corresponding author  
Eisuke Kondo  
Department of Pediatrics, Kawasaki Medical School,  
577 Matsushima, Kurashiki, 701-0192, Japan

Phone : 81 86 462 1111  
Fax : 81 86 464 1038  
E-mail: ekondo@med.kawasaki-m.ac.jp

## CASE REPORT

The patient was a 7-month-old girl who presented with fever, redness, swelling, and heat sensation spread to the entire left upper arm. She had received the BCG vaccination on the left upper arm on February 26, 20XX at 5 months of age. Around April 6, the patient presented to a different medical institution from the one where she received the vaccination because of redness and pustules at the BCG vaccination site. They were determined to be normal responses to the BCG vaccination, and her course was observed thereafter. However, she developed a fever of 39°C and redness, swelling, and heat sensation in the entire left upper arm, so on April 30, she presented to the medical institution again. After being treated with oral cefditoren pivoxil, she was referred to our hospital for inpatient treatment on May 1.

Other than the BCG vaccination, the patient's medical history was unremarkable. The patient had been delivered via spontaneous transvaginal delivery at 39 gestational weeks with a birth weight of 3,276 g. Neonatal asphyxia did not occur. The patient had received the following vaccines 3 times until 4 months of age, respectively: 13-valent pneumococcal conjugate vaccine; *Haemophilus*

*influenzae* type b conjugate vaccine; and diphtheria, tetanus, pertussis and polio combined vaccine. There was no family history of primary immunodeficiency. The mother had complained of pharyngeal pain 1 week prior to the onset of cellulitis in the child and was diagnosed with pharyngeal erythema at a local clinic, but details on medications are unknown.

### *Presentation on admission*

The patient's body temperature on admission was 37.2°C, pulse rate was 140 beats/min, blood pressure was 110/72 mmHg, and respiration rate was 28 breaths/min. Laboratory data are presented in Table 1. No pharyngeal erythema or cervical lymph node swelling was observed. The axillary lymph node was 1 cm in diameter and was mobile, elastic-hard, and tender to palpation. There was marked redness, swelling, and heat sensation over the entire left upper arm (Fig. 1) with mild redness at the BCG vaccination site. There were no abnormal findings in the chest or abdomen.

### *Course after hospitalization*

The patient was diagnosed with cellulitis, and intravenous administration of sulbactam/ampicillin was initiated at a dose of 50 mg/kg, 3 times/day.

Table 1. Laboratory findings on admission

Complete blood counts	Biochemistry data	Infection data
White blood cells: 21,060/ $\mu$ l	Total protein: 6.8 g/dl	anti-streptolysin O antibody: <24 IU/ml
Neutrophils: 44.0%	Albumin: 4.6 g/dl	
Lymphocytes: 46.0%	Total bilirubin: 0.9 mg/dl	<b>Immunoglobulin data</b>
Monocytes: 9.0%	Lactate dehydrogenase: 306 U/l	Immunoglobulin G: 305 mg/dl
Eosinophils: 1.0%	Alkaline phosphatase: 503 U/l	Immunoglobulin A: 17 mg/dl
Basophils: 0.0%	$\gamma$ -glutamyl transpeptidase: 19U/l	Immunoglobulin M: 25 mg/dl
Red blood cells: $4.82 \times 10^6$ / $\mu$ l	Aspartate aminotransferase: 44 U/l	
Hemoglobin: 11.9 g/dl	Alanine aminotransferase: 38 U/l	<b>Culture tests</b>
Hematocrit: 35.6%	Creatinine: 0.16 mg/dl	Blood: negative
Platelets: 417,000/ $\mu$ l	Urea nitrogen: 6 mg/dl	Pus from BCG scars: <i>S. pyogenes</i>
	Uric acid: 3.5 mg/dl	
<b>Electrolyte data</b>	Glucose: 118 mg/dl	<b>Urine test</b>
Sodium: 138 mEq/l	Total cholesterol: 181 mg/dl	Normal
Potassium: 4.5 mEq/l	Creatine kinase: 131 U/l	
Chlorine: 104 mEq/l	C-reactive protein: 4.27 mg/dl	
Calcium: 10.6 mg/dl		

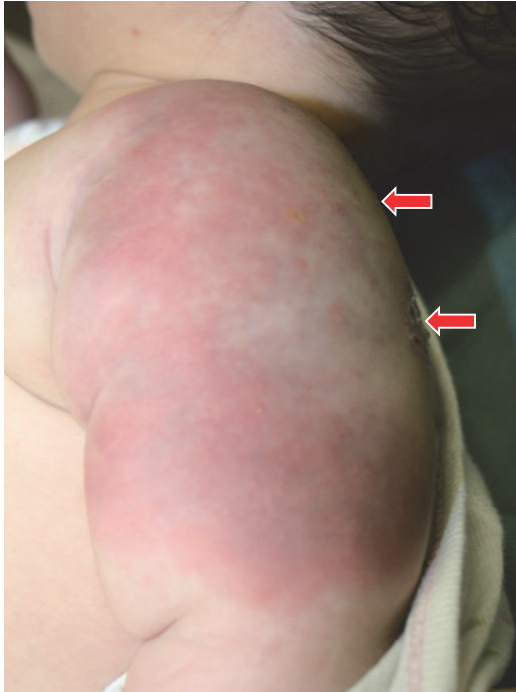


Fig. 1. Swelling and redness on the left upper arm on admission is shown. The red arrows indicate the BCG vaccination site.

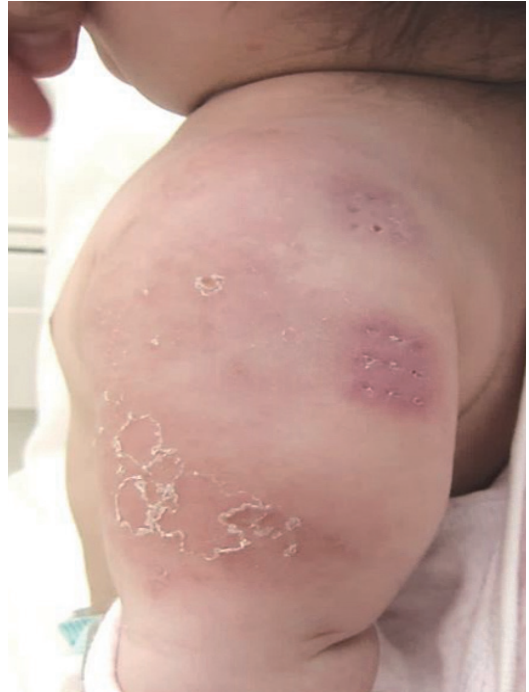

Fig. 2. Rapid improvement of inflammatory findings on the left upper arm on the 5th hospital day is shown.

Fever was not observed thereafter, and the axillary lymph node swelling and inflammatory findings on the left upper arm improved rapidly (Fig. 2). As *S. pyogenes* was detected from a culture of the pus from the scars at the BCG vaccination site, it was assumed to be the causative agent. Laboratory findings improved to: white blood cell count, 9,660/ $\mu\text{L}$ ; and C-reactive protein level: 0.12 mg/dL on the 5th hospital day. Antimicrobial drug treatment was changed to oral administration of amoxicillin at 16 mg/kg 3 times/day for 5 consecutive days, and the patient was discharged from the hospital on the same day. The appearance of BCG site in convalescent phase (8 days after hospital discharge) is shown in Fig. 3.

## DISCUSSION

Following BCG vaccination, redness and swelling at the vaccination site are generally observed around the 10th day, with a peak within 4 – 6

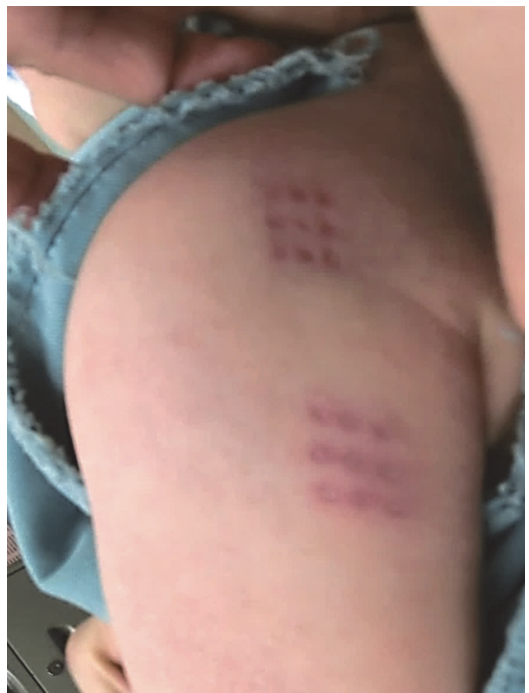

Fig. 3. The appearance of the BCG site 8 days after hospital discharge is shown.

Table 2. Adverse reactions to the BCG vaccine and their frequencies (in 100,000 vaccinated people: comparison of the reported adverse reactions between 1994-2005 and 2006-2010) (aggregation in Japan)

	1994-2005	2006-2010
Total number	5.30	9.80
Axillary lymph node swelling (diameter $\geq$ 1 cm)	3.90	5.60
Abscess at the local vaccination site	0.55	0.68
Osteitis/osteomyelitis	0.07	0.40
Cutaneous tuberculosis-like lesion	0.41	2.30
Systemic disseminated BCG infection	0.02	0.12
Other abnormal reactions	0.43	0.66
Lymph node swelling other than axilla	0.31	0.46
Acute local response	0.05	0.10
Others	0.07	0.10

From Reference 1)

weeks, followed by scabbing for up to 2 months and cicatrization after up to 3 months<sup>1, 2)</sup>. Deviations from this normal response include adverse reactions, such as axillary lymph node swelling, abscess at the local vaccination site, osteitis/osteomyelitis, systemic disseminated BCG infection, and cutaneous tuberculosis-like lesions (tuberculids)<sup>2-5)</sup>. Redness, swelling, and pimples a few days after BCG vaccination in children previously infected by tubercle bacillus (Koch's phenomenon)<sup>2)</sup> are usually not included as adverse reactions. When adverse reactions are suspected, it is important to conduct close examinations, including searching for a bacterium and observing the patient's course or providing treatment as required based on the time of vaccination, characteristics of eruption, and the patient's general condition. The patient in this case visited the medical institution for redness and pustules at the vaccination site as chief complaints 1 month after vaccination, but they were determined to be normal responses to the BCG vaccination. As there is no detailed record from that time, we can only presume that they were, at the time, usual responses, because 1 month after vaccination is when the greatest response at the vaccination site is observed, and it took another month for the redness, swelling, and heat sensation to spread to the entire left upper arm. The scars at the BCG vaccination site could be a portal of entry of microorganisms. It is often difficult to distinguish between cellulitis

and erysipelas, but we considered the skin lesion as cellulitis rather than erysipelas, because the lesion had an ambiguous boundary with the surrounding area.

A few patients are annually reported to develop cellulitis as an adverse reaction following vaccination, including following the BCG vaccine, as seen in our present case<sup>6, 7)</sup>. However, those cases are rarely reported in the literature, including cases reported abroad, and none of the published cases has involved the BCG vaccine. In Japan, the number of adverse reactions reported has increased on the whole since April 2005, when the BCG vaccine was injected directly into infants younger than 6 months without conducting a tuberculin skin test<sup>1, 8)</sup>. Following this, the target age for vaccination has been changed to younger than 1 year, and the standard period to receive vaccination has been newly set at 5 months to younger than 8 months since April 2013. Regarding the adverse reactions following BCG vaccination, the frequency of regional lymphadenitis is high and is thus well known, but reports on osteitis/osteomyelitis and skin manifestations such as tuberculids have increased during the period that the vaccine was administered to infants younger than 5 months (Table 2).

Risk factors for cellulitis include varicella, atopic dermatitis, injury, burn, diabetes mellitus, primary immunodeficiency, and medication (immunosuppressants, steroids, and biological

preparations), but the present patient had neither medical history or signs to suspect primary immunodeficiency nor family history, although the patient's immunoglobulin G level was slightly lower than the normal range for an infant of her age. Furthermore, she had never used drugs with immunosuppressive action, nor did she have any dermatoses, such as atopic dermatitis.

*Streptococci* account for approximately half of the causative agents of cellulitis and its frequency is as high as that of *Staphylococcus aureus*<sup>9-11)</sup>. Specifically, *S. pyogenes* should be considered as a causative pathogen for skin and soft tissue infections. Although there has been no report on cellulitis caused by this agent as an adverse reaction at the BCG vaccination site, it should be noted as a causative agent. As for the infection route, *S. pyogenes* may have been transmitted from the mother to the patient, as the mother had complained of pharyngeal pain 1 week prior to the onset of cellulitis in the child, but details are unknown.

We encountered a case in which cellulitis developed 2 months after BCG vaccination and spread from the vaccination site to the entire upper arm. *S. pyogenes* was assumed to be the causative agent. Thus, our case suggests that cellulitis caused by *S. pyogenes* should be noted as a potential adverse reaction following BCG vaccination.

#### ACKNOWLEDGEMENTS

We are indebted to Dr. Mutsumi Henmi. This research was supported by AMED under Grant Number [JP16mk0101012](#).

#### CONFLICT OF INTEREST

The corresponding author and Dr. Takaaki Tanaka declare no conflict of interest associated with this manuscript. Dr. Kazunobu Ouchi received honorariums from Taisho Toyama Pharmaceutical Co., Ltd., Pfizer Japan Inc., Japan Vaccine Co., Meiji Seika Pharma Co., Ltd., MSD K.K., Asahi Kasei

Corporation, and Astellas Pharma Inc., and also received grants from Teijin Pharma Ltd., Meiji Seika Pharma Co., Ltd., Mitsubishi Tanabe Pharma Corporation, JCR Pharmaceuticals Co., Ltd., Pfizer Japan Inc., Shionogi & Co., Ltd., Daiichi Sankyo Co., Ltd., Taisho Toyama Pharmaceutical Co., Ltd., Japan Vaccine Co., Ltd., and MSD K.K. Dr. Takashi Nakano received honorariums from Japan Vaccine Co., MSD K.K., Astellas Pharma Inc., Daiichi Sankyo Co., Mitsubishi Tanabe Pharma Corporation, Takeda Pharmaceutical Co., Ltd., Denka Seiken Co., Ltd., and Sanofi K.K.

#### REFERENCES

- 1) Mori T: The BCG vaccination programme of Japan. Recent problems and challenges. *Antibiotics & Chemotherapy* 29: 212-217, 2013 (Article in Japanese)
- 2) Mori T: BCG vaccine. *Antibiotics & Chemotherapy* 30: 484-491, 2014 (Article in Japanese)
- 3) Tokunaga O: BCG Sesshu. *The Journal of Public Health Practice* 78: 103-108, 2014 (Article in Japanese)
- 4) Venkataraman A, Yusuff M, Liebeschuetz S, Riddell A, Prendergast AJ: Management and outcome of Bacille Calmette-Guérin vaccine adverse reactions. *Vaccine* 33: 5470-5474, 2015
- 5) Ihara T: Managing adverse reactions after vaccination. *Journal of Clinical and Experimental Medicine* 244: 34-41, 2013 (Article in Japanese)
- 6) <http://www.mhlw.go.jp/stf/shingi2/0000092031.html> (2016.12.31)
- 7) <http://www.mhlw.go.jp/stf/shingi2/0000105632.html> (2016.12.31)
- 8) Okada K: BCG No Koka To Tekisetsuna Sesshujiki Ni Tsuite. *Japanese Journal of Pediatrics* 67: 529-533, 2014 (Article in Japanese)
- 9) Hadzovic-Cengic M, Sejtarija-Memisevic A, Koluder-Cimic N, Lukovac E, Mehanic S, Hadzic A, Hasimbegovic-Ibrahimovic S: Cellulitis--epidemiological and clinical characteristics. *Med Arch* 66: 51-53, 2012
- 10) Hayakawa K: Hokashikien. *Derma* : 31-35, 2011 (Article in Japanese)
- 11) Hayakawa K: Pathogenic Bacteria in Cellulitis. *Teikyō Medical Journal* 35: 73-79, 2012 (Article in Japanese)

