

〈Regular Article〉

## Efficacy and safety of temporary biliary stent for prevention of post-ERCP cholangitis after endoscopic common bile duct stone removal: a retrospective study

Tomohiro TANIKAWA, Noriyo URATA, Ken NISHINO, Mitsuhiro SUEHIRO, Takako SASAI, Miwa KAWANAKA, Ken HARUMA, Hirofumi KAWAMOTO

*Department of General Internal Medicine 2, Kawasaki Medical School*

**ABSTRACT** Although post-endoscopic retrograde cholangiopancreatography (ERCP) cholangitis (PEC) is not as severe as post-ERCP pancreatitis, this complication should not be disregarded. The aim of the present study was to evaluate the efficacy of a temporary biliary stent for prevention of PEC. Between April 2011 and May 2017, 190 patients underwent complete stone removal in a first session of ERCP at our hospital. Using propensity score matching, 72 pairs were enrolled in this study. After common bile duct (CBD) stone removal, the endoscopists decided to insert a temporary biliary stent if necessary. The incident rate of PEC was significantly lower in the stent group than the no-stent group (1% vs. 11%,  $p = 0.03$ ). The length of hospital stay was also significantly shorter in the stent group than the no-stent group (5 days vs. 7 days,  $p < 0.01$ ). In the stent group, one case had stent migration into the bile duct and two cases had a mooring stent at the papilla after 1 month. Multivariate analysis identified the pancreatic guide wire technique as a risk factor for PEC. We demonstrated that a temporary biliary stent reduced the incidence of PEC significantly and the outcome of its placement contributed to shortening the hospital stay. Furthermore, the placement of a temporary biliary stent caused fewer adverse effects than expected. Mooring stents were noted in three cases, which were confirmed by plain abdominal X-ray, but the patients had no symptoms. In two cases, the stent remained in the orifice of the papilla, and in one case it migrated into the CBD. All three stents were retrieved by elective endoscopic procedures. In conclusion, a temporary biliary stent can reduce the incidence of PEC and shorten the length of hospital stay without severe adverse outcomes. doi:10.11482/KMJ-E202046115 (Accepted on September 11, 2020)

Key words : Cholangitis, ERCP, Biliary stents

### INTRODUCTION

Endoscopic retrograde cholangiopancreatography

(ERCP) greatly impacts the diagnosis and treatment of hepatobiliary and pancreatic diseases. However,

---

Corresponding author  
Hirofumi Kawamoto  
Department of General Internal Medicine 2, Kawasaki  
Medical School, Kawasaki Medical School General  
Medical Center, 2-6-1 Nakasange, Kita-ku, Okayama,  
700-8505, Japan

Phone : 81 86 225 2111  
Fax : 81 86 232 8343  
E-mail: hirofumi.kawamoto@gmail.com

ERCP has a high risk of complications and requires high technical skill. Some complications result in serious morbidities, such as post-ERCP pancreatitis (PEP), bleeding, perforation, and cholangitis. The total incidence of these complications is reported to be 5-10%<sup>1-5</sup>. Of these complications, PEP is distinctive and many studies have been performed to avoid this morbidity. Previous studies reported that the incidence of PEP is 3.1-5.4%<sup>1, 6, 7</sup>. The mechanism of PEP is considered to be a spasm of the sphincter of Oddi, papillary edema, and epithelial injury to the pancreatic duct<sup>8, 9</sup>. Numerous studies have focused on preventing PEP, and the administration of rectal indomethacin and placement of a pancreatic stent have been reported as effective prevention methods.

Post-ERCP cholangitis (PEC) is also an adverse event that cannot be disregarded. PEC is reported to occur in 0.8-6.6% of ERCPs<sup>5, 10-13</sup>. Similar to PEP, mechanical stimulation of Vater's papilla by the ERCP procedure evokes a spasm of the sphincter of Oddi and papillary edema. The resulting biliary stasis and bacterial colonization cause PEC. Previous studies have reported that pathogenic bacteria in PEC are variable and mixed, especially *Enterobacteriaceae*, such as *Escherichia coli* and *Klebsiella* spp., *Enterococcus* spp., and *Streptococcus* spp.<sup>12, 14-16</sup>. However, unlike PEP, when PEC occurs, it is often rapidly improved by the administration of antibiotics or re-intervention to improve biliary stasis. Therefore, most PEC cases are not severe. Although the mortality of PEC is reported to be 0.3-0.9%<sup>11, 16</sup>, it can prolong the hospital stay and antimicrobial drug administration, and require another endoscopic treatment. Accordingly, PEC is an unnecessary morbidity and increases medical cost.

The risk factors for PEC are age, history of ERCP, hilar biliary obstruction, sphincter of Oddi dysfunction (SOD), and hilar biliary adenocarcinoma<sup>5, 17</sup>. Some reports have shown

that antibiotics can prevent PEC in high risk groups, and endoscopic nasobiliary drainage (ENBD) could reduce the incidence of PEC and the length of hospital stay<sup>18, 19</sup>. Currently, in clinical practice, the placement of biliary stents or ENBD catheters is often performed in cases in which PEC is considered possible at the time of treatment. However, after complete stone removal, no certain criteria for whether additional biliary drainage is necessary are accepted, and it is done at endoscopist's discretion. Furthermore, the choice of which drainage method to employ after complete stone removal is at the endoscopist's discretion, and is usually performed with placement of an ENBD catheter or biliary stent. However, ENBD is uncomfortable for the patient and dislocation often happens. When a biliary stent is employed, it is necessary to remove it endoscopically. To overcome the drawbacks of the present methods, a temporary biliary stent that dislodges spontaneously after food intake is favorable. The aim of the present study was to investigate the efficacy and safety of a temporary biliary stent in preventing PEC.

## PATIENTS AND METHODS

### Patients

Between April 2011 and May 2017, 2055 consecutive patients aged  $\geq 20$  years underwent common bile duct (CBD) stone removal at Kawasaki General Medical Center. A total of 190 of these patients who had intact papilla and underwent complete stone removal in the first session of ERCP were enrolled in this study. Our ethical committee approved this study and the indication for a temporary stent. The flow diagram of patient selection is given in Fig. 1 CBD stones were detected and evaluated by computed tomography (CT), magnetic resonance cholangiopancreatography (MRCP), abdominal ultrasound, and/or endoscopic ultrasound (EUS) before ERCP. Patients who had concomitant severe pancreatitis or

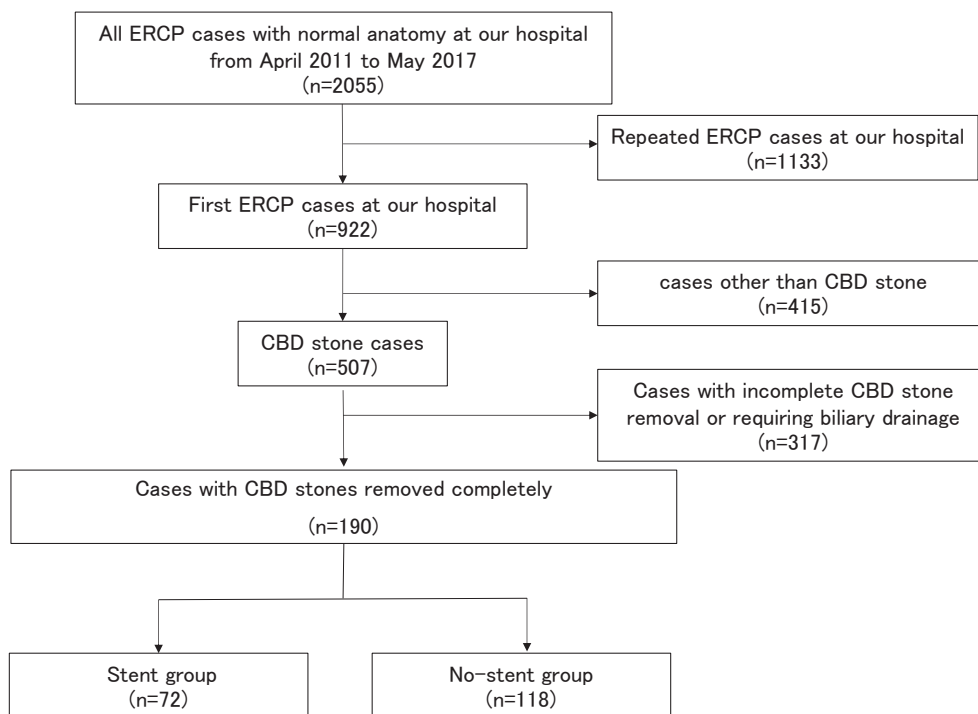


Fig. 1. Flow diagram of patient selection

who received a biliary stent before complete stone removal were excluded from the study. The patients were separated into two groups: stent and no-stent. The two groups were compared with respect to outcomes. We used propensity score matching to reduce selection bias.

#### Procedure

We used a side-viewing endoscope (JF - 260V or TJF - 260V; Olympus Co. Ltd., Tokyo, Japan) and started cannulation of the bile duct using the conventional contrast method. In the case of difficult biliary cannulation, we used the pancreatic guide wire (PGW) technique, wire-guided cannulation (WGC), and precutting papillotomy according to the judgement of the endoscopist. The starters were trainees and, in difficult cases, the trainer helped them (partly or almost completely).

After CBD access, endoscopic sphincterotomy (EST), endoscopic papillary balloon dilation

(EPBD), or endoscopic papillary large balloon dilation (EPLBD) were performed on the papilla before extraction of the stones. The stones were removed by a retrieval balloon or basket, and mechanical lithotripsy was used to crush large stones if necessary. Complete stone removal was certified by balloon occluded cholangiogram. To avoid subsequent obstructive cholangitis due to edema of the papilla, a temporary biliary stent was deployed in high-risk patients at the endoscopist's discretion. We had no rigid criteria on the temporary stent placement. However, we usually deployed the temporary stent, when it took a long time to complete the endoscopic treatment in difficult cases, such as of large stone removal, difficult biliary cannulation and so on. The temporary biliary stent used in this study was a 5Fr.-5 cm Geenen-type pancreatic stent (COOK Co. Ltd., Winston Salem, US), which has a flap on one side (Fig. 2) but no flap on the side placed in the bile

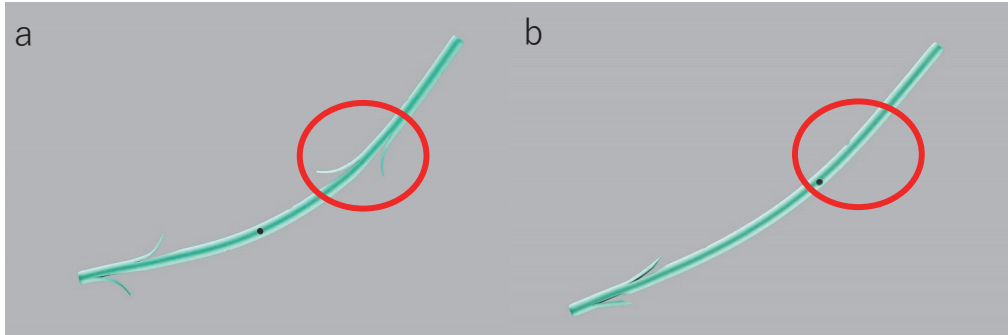


Fig. 2. Geenen-type pancreatic duct stent  
 a: Conventional stent with flaps on both sides. b: Temporary stent without a flap on the side to be inserted into the common bile duct (compare the red circles).

duct. Therefore, it cannot anchor in the bile duct and drops after starting a meal. After certifying complete stone removal, this stent was inserted by the over-the-wire technique. In all cases, a blood test was performed the next morning to monitor for adverse effects of the treatment, and patients who were suspected of having complications, such as cholangitis or pancreatitis, were followed up with blood tests and medical imaging. In the stent group, the dislodgement of the deployed stent after commencement of a meal was confirmed by abdominal X-ray, and if it remained in the CBD or gastrointestinal tract 1 month later, endoscopic removal was performed.

#### *Study outcome and definition*

The primary outcome was the incidence rate of PEC. Secondary outcomes were length of hospital stay, the incidence rate of other adverse events, and necessity of re-intervention. In this study, PEC included aggravation or no improvement in acute cholangitis comparison to the patient's status before treatment.

Based on several previous studies, we defined PEC as follows excluding other infection or PEP<sup>12, 16, 20</sup>: body temperature > 38°C with upper right abdominal pain and/or abnormal blood examination (white blood cell [WBC] > 12,000/

$\mu\text{L}$  and C-reactive protein [CRP] > 3.0 mg/dL in patients without cholangitis before the procedure; WBC elevation and CRP increased by more than 3.0 mg/dL compared to pre-procedure in patients with cholangitis before the procedure).

Adverse events were defined by the lexicon for endoscopic adverse events by the American Society of Gastrointestinal Endoscopy. The endoscopist decided to perform re-intervention whenever the liver function test and cholangitis did not improve enough with conservative treatment.

#### *Statistical analysis*

Continuous variables were compared between two groups using the Mann-Whitney U-test and expressed as median and interquartile range (IQR). Categorical variables were compared using Fisher's exact test. As a sub-analysis of this study, multivariate analysis using Fisher's exact test for categorical variables was carried out to evaluate the risk factors for PEC.

Propensity score matching analysis was performed to reduce the influence of differences in baseline characteristics between two groups. Two groups were matched using 1:1 nearest neighbor-matching without replacement. Rigorous adjustments were carried out for the following nine factors: age, gender, history of EST, blood examination (WBC,

alanine transaminase [ALT],  $\gamma$ -glutamyltransferase [ $\gamma$ GT], and CRP), gallbladder stone pancreatitis, diverticulum at the peripapillary portion, cannulation method, procedure time, and endoscopic procedure (EST, EPBD, or EPLBD).

All statistical analyses were performed with IBM SPSS Statistics version 26 (IBM, Armonk, NY, US). For all analyses,  $p < 0.05$  was considered significant.

## RESULTS

### Patient characteristics

ERCP was performed in 2055 patients at our hospital during the study period. Among these patients, 1865 were excluded based on the eligibility criteria, and 190 patients were selected for the study. A temporal and prophylactic biliary stent was deployed in 72 patients (prophylactic stent [PS] group) and not deployed in 118 patients (no-stent [NS] group). Propensity score matching was conducted, extracting 144 patients, 72 patients for each group. Table 1 provides the patients'

demographic data and procedural parameters, including gender, age, blood examination (WBC, ALT,  $\gamma$ GT, and CRP), gallbladder stone pancreatitis, biliary cannulation time, total procedure time, and cannulation technique. Before propensity matching score, we found no significant baseline parameters except the PGW technique ( $p = 0.04$ ). After propensity score matching, we found no significant difference among parameters.

### PEC and the length of hospital stay

Table 2 shows the primary and secondary outcomes of both groups after endoscopic stone treatment. The incidence rate of PEC was significantly lower in the PS group than the NS group ( $n = 1$ , 1% vs.  $n = 8$ , 11%;  $p = 0.03$ ). All cases of PEC were mild to moderate. Among cholangitis patients, seven were treated conservatively and four were treated with immediate endoscopic re-intervention, including biliary stent deployment performed the following day. However, no stone was found during the procedure. The symptoms related to cholangitis

Table 1. Baseline characteristics of the study patients

	Overall cohort (n=190)			Propensity-matched cohort (n=144)		
	PS group (n=118)	NS group (n=72)	P value	PS group (n=72)	NS group (n=72)	P value
Age, years	72 (62-85)	75 (66-81)	0.75	72 (62-85)	74 (65-82)	0.59
Sex, male	37 (51%)	62 (53%)	0.88	37 (51%)	39 (54%)	0.87
Diverticular(%)	23 (32%)	47 (40%)	0.28	23 (32%)	23 (32%)	1
WBC	6140 (4797-9292)	7015 (5398-9078)	0.22	6140 (4797-9292)	5960 (5015-7653)	0.73
$\gamma$ -GT	211 (64-410)	149 (65-351)	0.34	211 (64-410)	188 (67-334)	0.47
ALT	94 (23-214)	61 (23-184)	0.29	94 (23-214)	63 (28-207)	0.65
CRP	0.72 (0.17-3.21)	0.52 (0.15-4.48)	0.79	0.72 (0.17-3.21)	0.47 (0.13-2.32)	0.27
Cannulation time, minutes	3 (1-12)	3 (1-10)	0.95	3 (1-12)	3 (1-9)	0.44
Cannulation method						
PGW	3 (4%)	15 (13%)	0.04	3 (4%)	6 (8%)	0.49
precut	7 (10%)	13 (11%)	0.49	7 (10%)	5 (7%)	0.76
Procedure						
EST	65 (90%)	108 (92%)	0.8	65 (90%)	66 (92%)	1
EPBD	3 (4%)	5 (4%)	1	3 (4%)	4 (6%)	1
EPLBD	16 (22%)	19 (16%)	0.34	16 (22%)	12 (17%)	0.53
EPS	9 (13%)	21 (18%)	0.41	9 (13%)	11 (15%)	0.81
Procedure time, minutes	27 (19-36)	27 (19-37)	0.94	27 (19-36)	24 (18-38)	0.59

Data are presented as median (interquartile range) or n (%). PS: prophylactic stent, NS: no-stent, WBC: white blood cell, ALT: alanine transaminase,  $\gamma$ GT:  $\gamma$ -glutamyltransferase, CRP: C-reactive protein, PGW: pancreatic guide wire technique, EST: endoscopic sphincterotomy, EPBD: endoscopic papillary balloon dilation, EPLBD: endoscopic papillary large balloon dilation, EPS: endoscopic pancreatic stent.

Table 2. Outcomes and adverse events after complete stone removal

	Overall cohort (n=190)			Propensity-matched cohort (n=144)		
	PS group (n=72)	NS group (n=118)	P value	PS group (n=72)	NS group (n=72)	P value
Post-ERCP cholangitis	1 (1%)	10 (8%)	0.09	1 (1%)	8 (11%)	0.03
Length of hospital stay, days	5 (3-7)	6 (4-9)	0.028	5 (3-7)	7 (5-11)	< 0.01
Post-ERCP pancreatitis	5 (7%)	6 (5%)	0.83	5 (7%)	4 (6%)	1
Bleeding	1 (1%)	1 (1%)	0.71	1 (1%)	1 (1%)	1
Immediate re-intervention	1 (1%)	3 (3%)	1	1 (1%)	3 (4%)	0.62
Biliary drainage	1 (1%)	3 (3%)	1	1 (1%)	3 (4%)	0.62
Elective re-intervention	3 (4%)	–	–	3 (4%)	–	–
Stent migration	1 (1%)	–	–	1 (1%)	–	–
Stent mooring	2 (3%)	–	–	2 (3%)	–	–

Data are presented as median (interquartile range) or n (%).

PS: prophylactic stent, NS: no-stent,

improved after these therapies. The cause of PEC in the PS group was inadvertent stent dislocation within a day after ERCP, which was confirmed by CT the following day. The mean length of hospital stay was significantly shorter in the PS group than the NS group (5 days vs. 7 days,  $p < 0.01$ ).

#### Adverse events

Table 2 also provides the other adverse events in both groups. We noted no mortality or significant differences between the two groups. In the PS group, we identified one case of stent migration into the bile duct and two cases of stent mooring in the orifice of the bile duct 1 month after the first treatment, but they had no symptoms. Endoscopic stent removal was performed in these patients. However, these procedures were conducted electively. One case who had stent migration had a large duodenal diverticulum beside the papilla.

#### Risk factors for PEC in all patients

Eleven patients (6%) in the cohort were diagnosed with PEC. Multivariate analysis for the risk of PEC is given in Table 3. The parameters considered as the risk factor of PEC were selected based on previous studies<sup>5, 13</sup>. Multivariate analysis showed that only PGW technique was a risk factor for PEC.

Table 3. Multivariate analysis of the risk factors for post-ERCP cholangitis

	HR(95% CI)	P value
Age (> 75 y.o.)	0.65 (0.17-2.50)	0.54
Precut	0.70 (0.10-4.72)	0.71
PGW	11.70 (2.61-52.20)	< 0.01
EST	0.68 (0.10-4.68)	0.69
EPBD	3.67 (0.25-54.30)	0.35
EPLBD	2.27 (0.48-10.70)	0.3
Procedure time (>30 min)	1.74 (0.40-7.47)	0.46

CI: confidence interval, PGW: pancreatic guide wire technique, EST: endoscopic sphincterotomy, EPBD: endoscopic papillary balloon dilation, EPLBD: endoscopic papillary large balloon dilation.

## DISCUSSION

Many adverse events after ERCP have long been discussed. Although PEP is a major adverse event, PEC is also not negligible. We hypothesized that edema of the papilla after complete stone removal induces PEC due to disturbances in bile juice flow by repeated mechanical stimuli with a basket or balloon catheter in addition to stone impaction in the papilla due to incomplete stone removal. Therefore, we expect that a temporary biliary stent may be effective for prophylaxis of PEC due to the edema in the papilla. Despite the retrospective nature of this study, we demonstrated that a temporary biliary stent reduced the incidence of PEC significantly and the outcome of its placement contributed to shortening the hospital stay. Furthermore, the placement of a temporary biliary stent caused fewer

adverse effects than expected.

Yang *et al* reported that ENBD could also prevent PEC and shorten the length of hospital stay<sup>19)</sup>. ENBD certainly can achieve adequate biliary decompression after stone removal. As incomplete biliary drainage is one of the risk factors for PEC<sup>1)</sup>, ENBD established a preventive effect. Although ENBD has the advantage of prophylaxis for PEC, the patients who undergo this procedure suffer from discomfort due to placement of the ENBD catheter, which is often withdrawn unconsciously by elder patients. In contrast, a temporary biliary stent could result in almost the same outcome as ENBD regarding the prevention of PEC. Furthermore, this stent spontaneously drops off within 1 month in most cases, and only a few cases require another endoscopic intervention.

However, we noted some adverse events regarding the placement of a temporary biliary stent after stone removal. In this study, mooring stents were noted in three cases, which were confirmed by plain abdominal X-ray, but the patients had no symptoms. In two cases, the stent remained in the orifice of the papilla, and in one case it migrated into the CBD. All three stents were retrieved by elective endoscopic procedures. Unfortunately, we could not demonstrate why a temporary biliary stent remained in the CBD. It likely depended on some anatomical cause in each patient. In the stent migration case, Vater's papilla was located in the duodenal diverticulum, but we were uncertain if this was the cause. The diameters of the employed stents were thin. Therefore, there was a possibility of migration after EST or EPLBD, though the incidence was not higher than expected. Additionally, there was no patients diagnosed as recurrent cholangitis due to obstruction of temporary biliary stent or reflux of duodenal content.

In this study, we tried to calculate the risk factors related to inducing PEC. Multivariate analysis showed that only the PGW technique was a

risk factor for PEC, which is required when an endoscopist has difficulty achieving successful biliary cannulation in a floppy papilla. Therefore, employment of the PGW technique means a difficult biliary cannulation, which has the potential for difficult stone removal that induces edema of the papilla. However, a previous study showed that the double guide wire endoscopic technique, in which one guide wire is placed in the pancreatic duct, has a lower incidence rate of PEC than a control group<sup>13)</sup>. This technique is employed in difficult CBD access strategies. In that study, the success rate of CBD access was significantly higher in the study group than the control group. Consequently, the success rate of biliary drainage is also different. Therefore, we cannot compare our data and the data from the previous study. The procedure and cannulation time are expected to be related to the duodenal papilla edema. However, the consuming time highly depends on endoscopists' skill, especially regarding cannulation time. As participation of a trainee was a confounding factor, we did not analyze the cannulation time.

This study has several limitations, including the retrospective nature, small number of cases, being a single center study, and uncertain criteria for insertion of a temporary biliary stent. Although we could safely use this temporary biliary stent without adverse events in almost all patients, there may be other adverse events that we did not encounter during the study period. We should at least avoid use it for patients with intradiverticular papilla and gastrointestinal obstruction. Therefore, we have to consider the stent insertion criteria and a randomized trial to determine the risk factors and efficacy of temporary drainage for preventing PEC. However, it is meaningful that this study demonstrated the potential effectiveness of plastic stents to reduce PEC.

In conclusion, we suggest that a temporary biliary stent can reduce the incidence of PEC and

shorten the length of hospital stay. For patients with risk factors for PEC, we may consider aggressive insertion of temporary biliary stents.

### Conflicts of interest

There are no conflicts of interest to declare.

### REFERENCES

- 1) Freeman ML, Nelson DB, Sherman S, *et al.*: Complications of endoscopic biliary sphincterotomy. *N Engl J Med.* 1996; 335: 909-18. doi: 10.1056/NEJM199609263351301.
- 2) Freeman ML, DiSario JA, Nelson DB, *et al.*: Risk factors for post-ERCP pancreatitis: a prospective, multicenter study. *Gastrointest Endosc.* 2001; 54: 425-34. doi: 10.1067/mge.2001.117550.
- 3) Vandervoort J, Soetikno RM, Tham TC, *et al.*: Risk factors for complications after performance of ERCP. *Gastrointest Endosc.* 2002; 56: 652-6. doi: 10.1067/mge.2002.129086.
- 4) Wang P, Li ZS, Liu F, *et al.*: Risk factors for ERCP-related complications: a prospective multicenter study. *Am J Gastroenterol.* 2009; 104: 31-40. doi: 10.1038/ajg.2008.5.
- 5) Chen M, Wang L, Wang Y, Wei W, Yao YL, Ling TS, Shen YH, Zou XP: Risk factor analysis of post-ERCP cholangitis: A single-center experience. *Hepatobiliary Pancreat Dis Int.* 2018; 17: 55-58. doi: 10.1016/j.hbpd.2018.01.002.
- 6) Glomsaker T, Hoff G, Kvaloy JT, Soreide K, Aabakken L, Soreide JA, Norwegian Gastronet ERCP Group: Patterns and predictive factors of complications after endoscopic retrograde cholangiopancreatography. *The British journal of surgery.* 2013; 100: 373-80. doi: 10.1002/bjs.8992.
- 7) Katsinelos P, Lazaraki G, Chatzimavroudis G, *et al.*: Risk factors for therapeutic ERCP-related complications: an analysis of 2,715 cases performed by a single endoscopist. *Ann Gastroenterol.* 2014; 27: 65-72.
- 8) Akashi R, Kiyozumi T, Tanaka T, Sakurai K, Oda Y, Sagara K: Mechanism of pancreatitis caused by ERCP. *Gastrointest Endosc.* 2002; 55: 50-4. doi: 10.1067/mge.2002.118964.
- 9) Sofuni A, Maguchi H, Mukai T, *et al.*: Endoscopic pancreatic duct stents reduce the incidence of post-endoscopic retrograde cholangiopancreatography pancreatitis in high-risk patients. *Clin Gastroenterol Hepatol.* 2011; 9: 851-8; quiz e110. doi: 10.1016/j.cgh.2011.06.033.
- 10) Ciriza C, Dajil S, Jimenez C, Urquiza O, Karpman G, Garcia L, Romero MJ: Five-year analysis of endoscopic retrograde cholangiopancreatography in the Hospital del Bierzo. *Rev Esp Enferm Dig.* 1999; 91: 693-702.
- 11) Christensen M, Matzen P, Schulze S, Rosenberg J: Complications of ERCP: a prospective study. *Gastrointest Endosc.* 2004; 60: 721-31. doi: 10.1016/s0016-5107(04)02169-8.
- 12) Kim NH, Kim HJ, Bang KB: Prospective comparison of prophylactic antibiotic use between intravenous moxifloxacin and ceftriaxone for high-risk patients with post-ERCP cholangitis. *Hepatobiliary Pancreat Dis Int.* 2017; 16: 512-518. doi: 10.1016/S1499-3872(17)60056-0.
- 13) Laquiere A, Desilets E, Belle A, Castellani P, Grandval P, Laugier R, Penaranda G, Lecomte L, Boustiere C: Double guidewire endoscopic technique, a major evolution in endoscopic retrograde cholangiopancreatography: Results of a retrospective study with historical controls comparing two therapeutic sequential strategies. *Dig Endosc.* 2017; 29: 182-189. doi: 10.1111/den.12740.
- 14) Leung JW, Ling TK, Chan RC, Cheung SW, Lai CW, Sung JJ, Chung SC, Cheng AF: Antibiotics, biliary sepsis, and bile duct stones. *Gastrointest Endosc.* 1994; 40: 716-21.
- 15) Parker HW, Geenen JE, Bjork JT, Stewart ET: A prospective analysis of fever and bacteremia following ERCP. *Gastrointest Endosc.* 1979; 25: 102-3. doi: 10.1016/s0016-5107(79)73385-2.
- 16) Ertuğrul I, Yüksel I, Parlak E, Cicek B, Ataseven H, Başar O, Ibis M, Sasmaz N, Sahin B: Risk factors for endoscopic retrograde cholangiopancreatography-related cholangitis: a prospective study. *Turk J Gastroenterol.* 2009; 20: 116-21.
- 17) Miyatani H, Mashima H, Sekine M, Matsumoto S: Post-ERCP biliary complications in patients with biliary type sphincter of Oddi dysfunction. *Sci Rep.* 2018; 8: 9951. doi: 10.1038/s41598-018-28309-w.
- 18) Kager LM, Sjouke B, van den Brand M, Naber TH, Ponsioen CY: The role of antibiotic prophylaxis in endoscopic retrograde cholangiopancreatography;



- a retrospective single-center evaluation. *Scand J Gastroenterol.* 2012; 47: 245-50. doi: 10.3109/00365521.2011.643482.
- 19) Yang J, Peng JY, Pang EJ, Chen W : Efficacy of endoscopic nasobiliary drainage for the prevention of post-endoscopic retrograde cholangiopancreatography pancreatitis and cholangitis after repeated clearance of common bile duct stones: experience from a Chinese center. *Dig Endosc.* 2013; 25: 453-8. doi: 10.1111/den.12013.
- 20) Wan X, Chen S, Zhao Q, Li T, Luo S, Cai X, Ren Y, Yu L, Li B: The efficacy of temporary placement of nasobiliary drainage following endoscopic metal stenting to prevent post-ERCP cholangitis in patients with cholangiocarcinoma. *Saudi J Gastroenterol.* 2018; 24: 348-354. doi: 10.4103/sjg.SJG\_94\_18.